

Osteopathic Techniques for the hip and knee in pediatric patients.

Doris Newman, DO, FAAO

Newman Osteopathic & Wellness, LLC

Fort Lauderdale, FL 33305

dorisnewman9@gmail.com

Disclosures

- None

Objectives

1. Participants will be able to discuss the developmental process and implications when utilizing OMT in the treatment of children with hip and knee problems.
2. Participants will be able to identify common hip and knee pathologies in children.
3. Participants will be able to apply osteopathic manipulative treatment to children with hip and knee pathology.

Outline of presentation

Discussion Topics

- Developmental considerations
 - Somatosensory – Motor - Cognition
 - Hypotonia and its effects
- Non-weight bearing vs weight bearing assessments and age groups
- Development of the bony structures
 - Growth plates and OMT of the long bones


Techniques

- Pelvis/Hip
 - SI articular technique
 - CS – psoas, piriformis, hip ADDuctors
 - BLT – Innominate, hip rotator muscles using the femur as a long lever
- Hip/Knee
 - Assessment of femur and tibia standing and seated
 - MET
 - Femur
 - Tibia
 - BLT knee joint
 - distal femur and proximal tibia
 - Hamstring spread
 - Fluid techniques entire LE


Three components of cognitive function

- Ability to attend
 - And record
 - Sensory information
 - Motor coordination
- Ability to integrate
 - From the context of all other experiences
 - Contextual
- Ability to interpret
 - Derive meaning and respond

Shapes




- Attend
- Integrate
- Interpret



- Attend
- Integrate
- Interpret


Changing Shapes

Spatial Relationship of Shapes



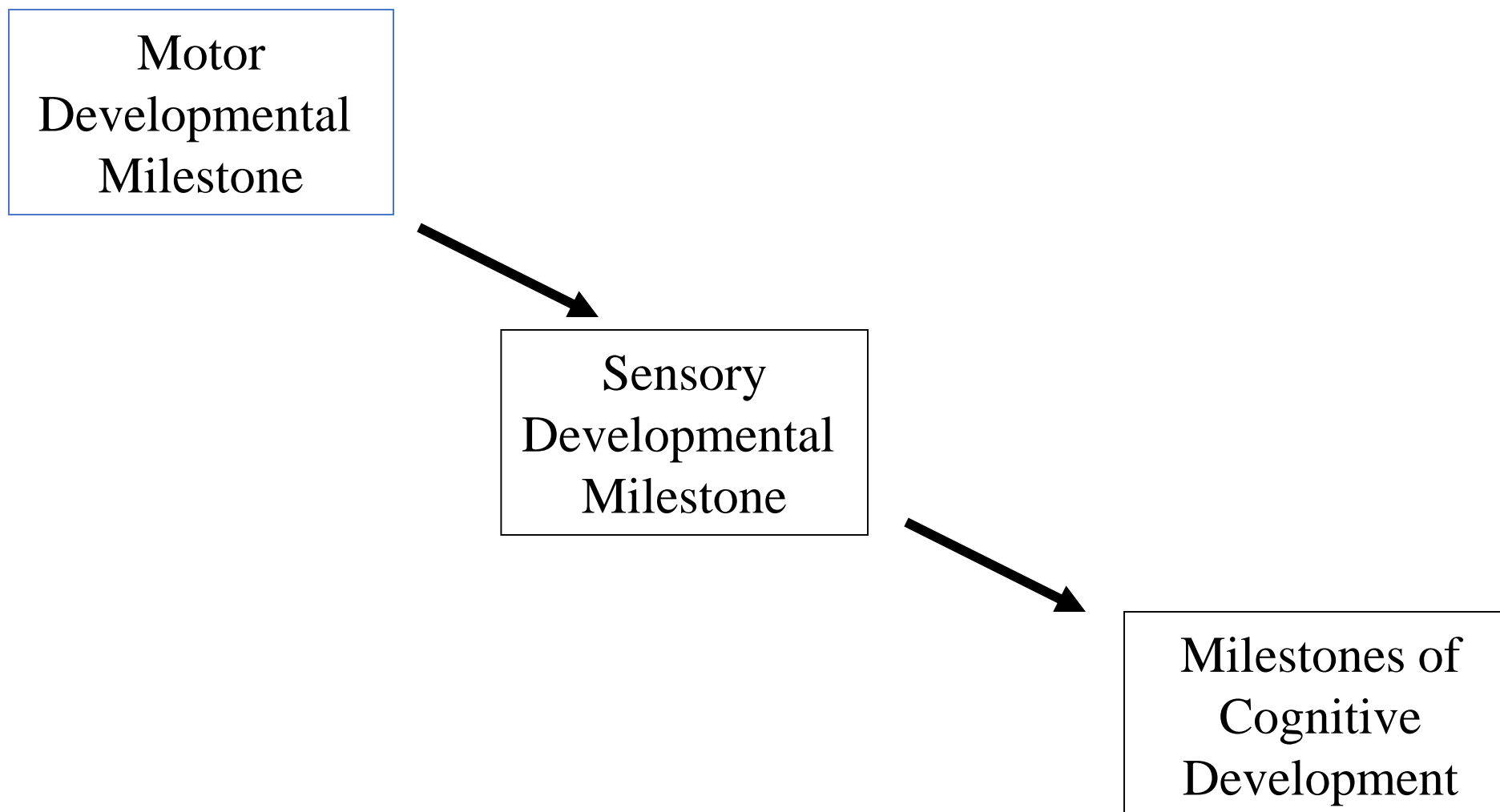
- Attend
- Integrate
- Interpret

Mature Language and Meaning

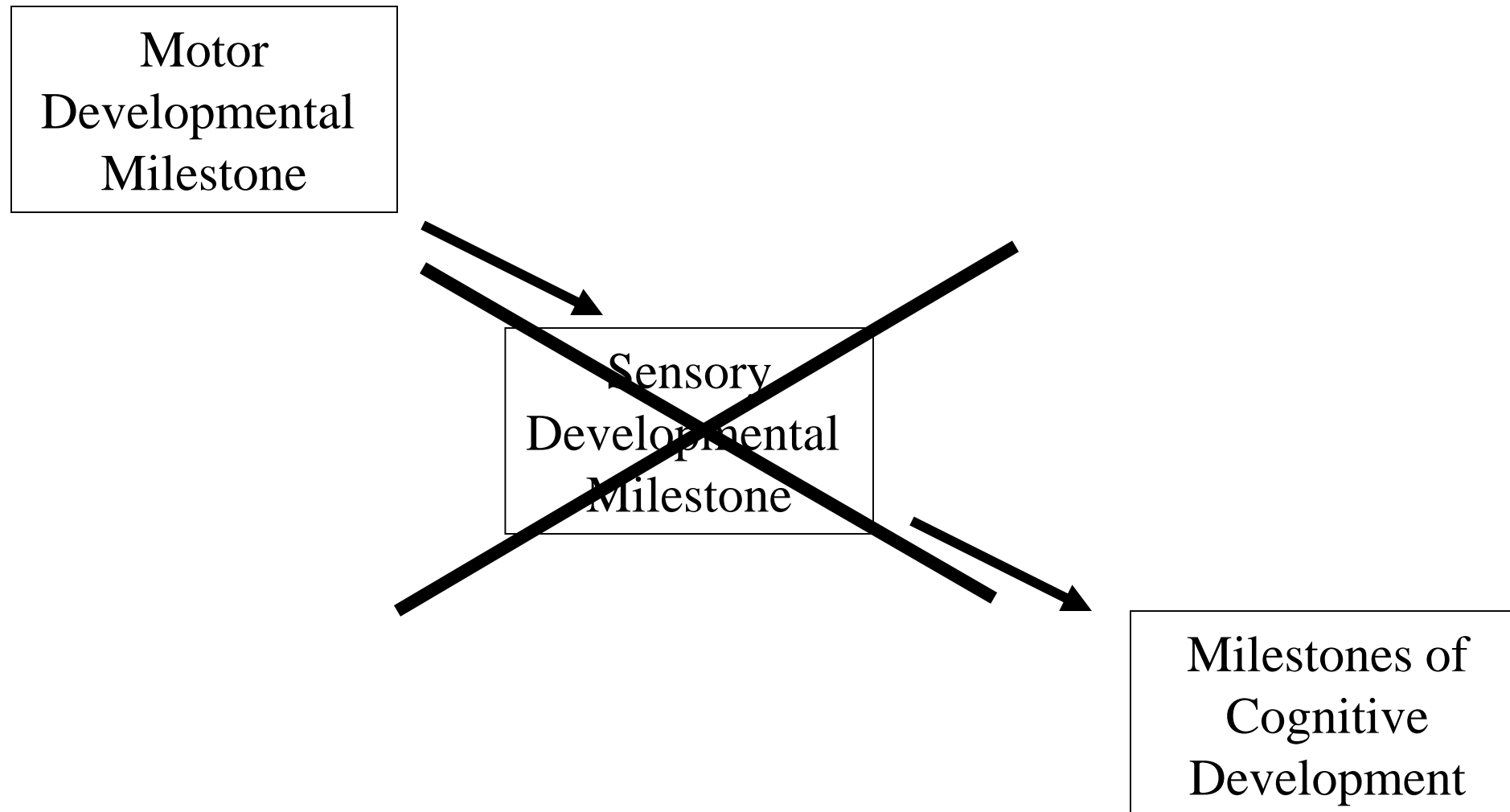


- Attend
- Integrate
- Interpret

Development Cascade Flow Chart thru Milestones



Difficulty in any one of the developmental milestone areas will negatively affect all 3 areas



Motor Development

- Proceeds
 - cephalad to caudad and
 - proximal to distal
- Muscle tone dictates motor development process
 - Intrauterine
 - Birth
 - Infancy



In motor control:

POSTURE → primary

CONTROLLED MOVEMENT → secondary

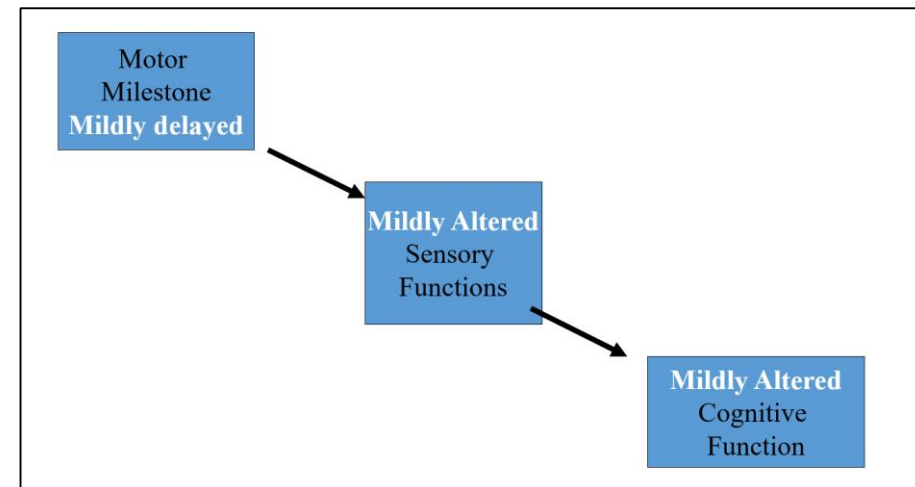
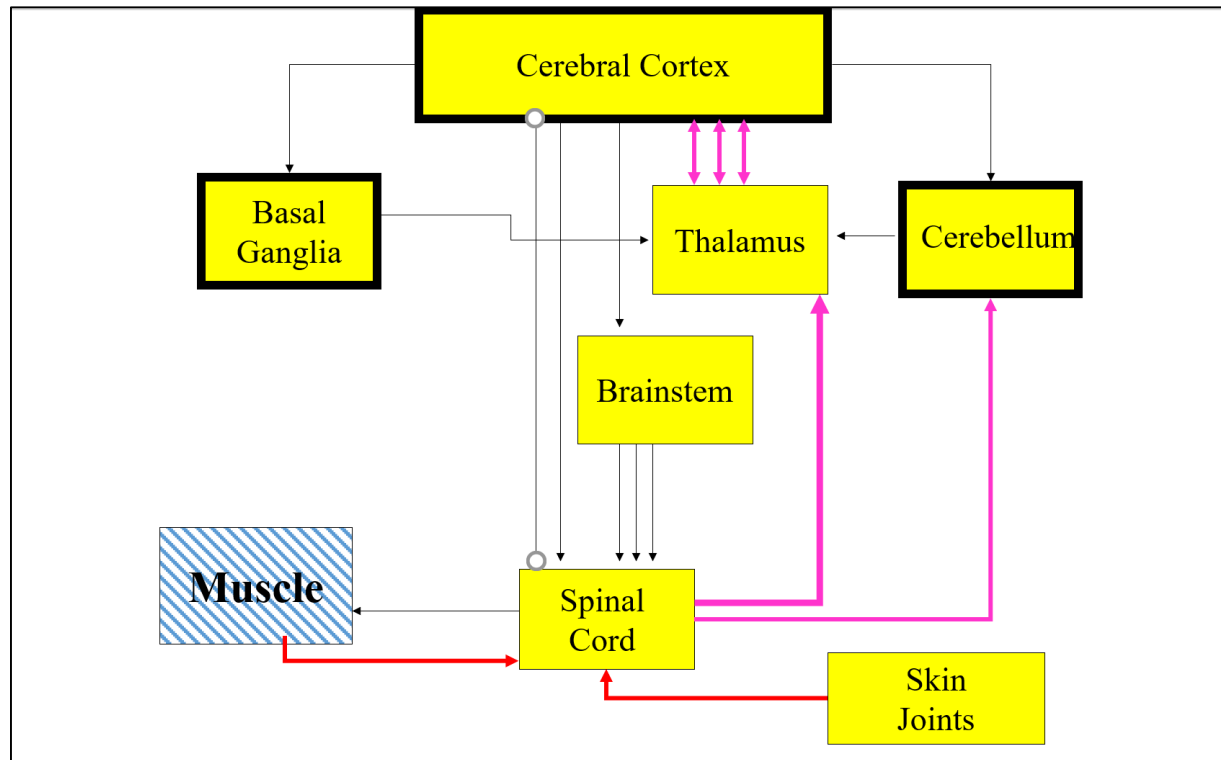
“Stability before Mobility”



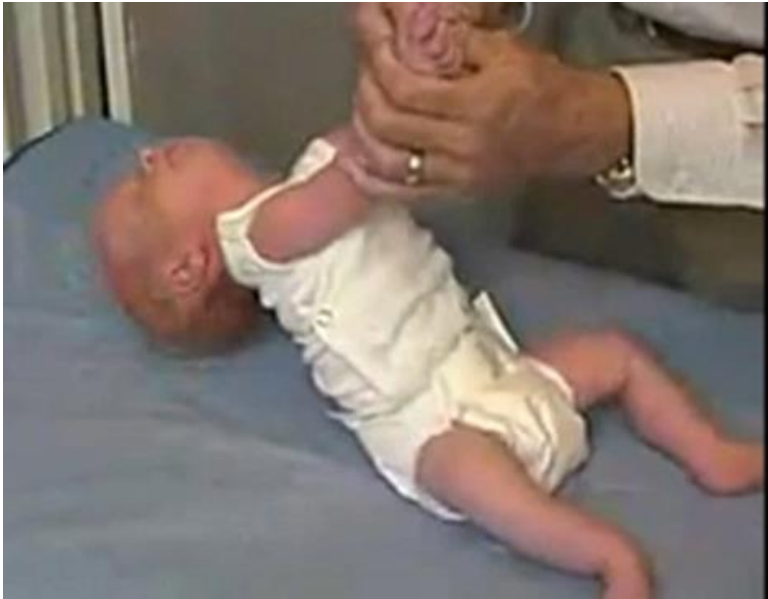Interference in either the Motor Development OR Sensory Development will negatively affect Cognitive Development

Hypotonia – mild cases are primarily a muscle disease and often missed

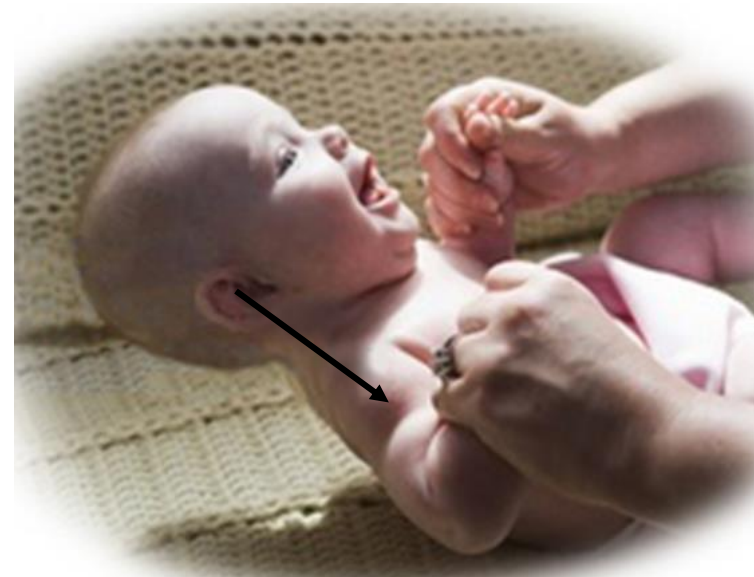Proprioceptor information coming back into the central nervous system will be altered.



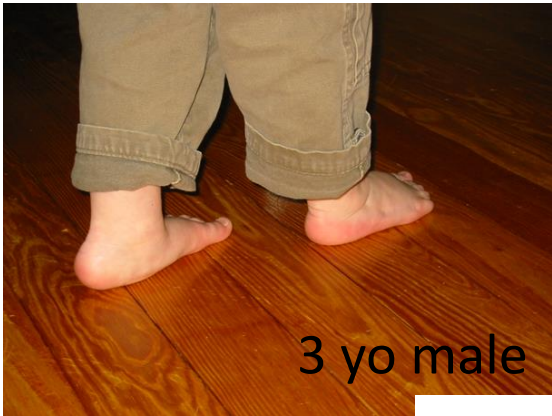Hypotonia- head lag past 3 mo



Normal: by 3mo head even
With shoulder on pull to sit



Hypotonia and Pes Planus (Flat Foot)



Can pes planus help identify low tone infants and children?

- 97% prevalence ages 0-2yrs
- 54% by age 3
- 24% by age 6 THUS: BW 3-6 years most important
- 4% by age 10

Risk factors:

- Joint laxity, **W-sitting**, Male, Obesity

Two theories of persistent flat foot in children:

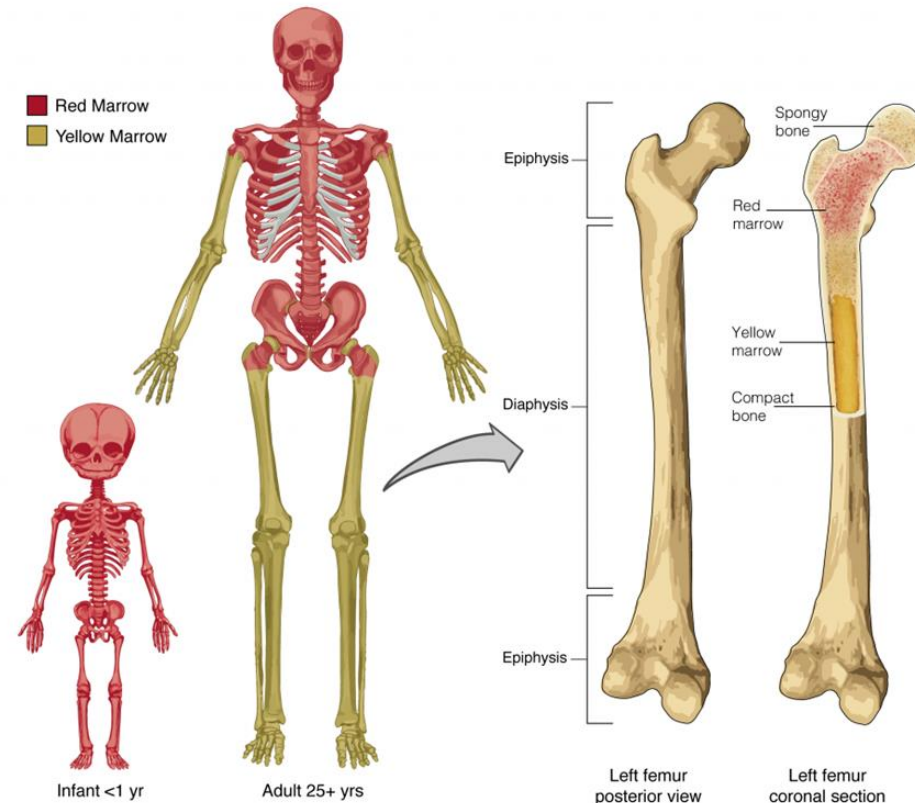
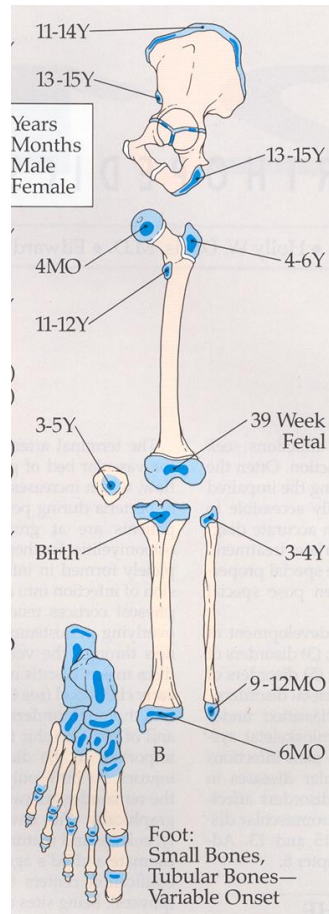
- 1) Poor muscle strength:
 - +EMG weakness of extensor mm correlated with severity of flat foot
- 2) Osseous-ligamentous complex
 - 43% of symptomatic flat foot also had IR of the tibia

Persistent Flat foot issues:

- Pain other symptoms higher up the chain
- Increased metabolic work
- Missed motor tone issues
- Missed indicators of other issues

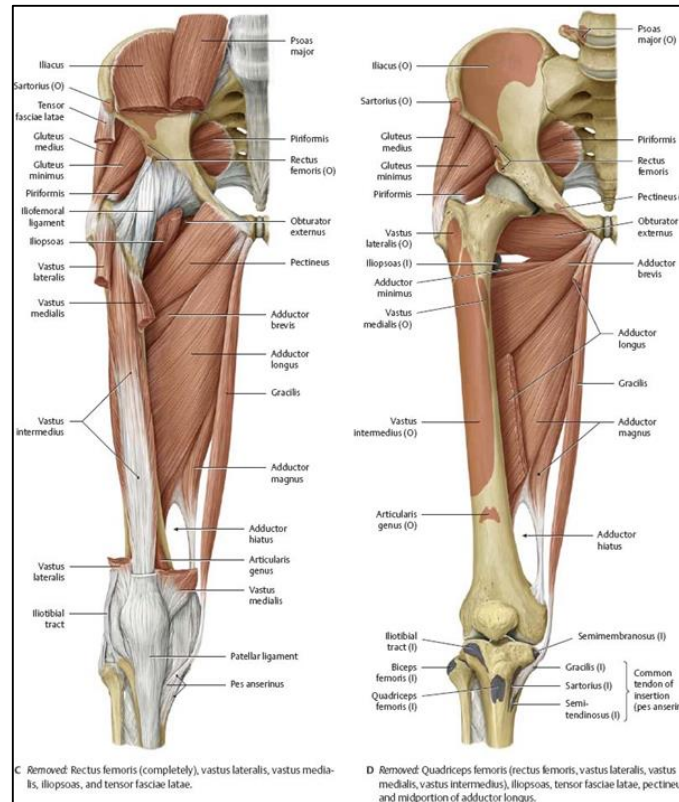
Carr JB, Yang S, Lather LA. Pediatric Pes Planus: A State-of-the-Art Review. Pediatrics. 2016;137(3):e20151230

Bone Developmental Considerations in the Pediatric patient



Biomechanical Assessment of the LE & Pelvis

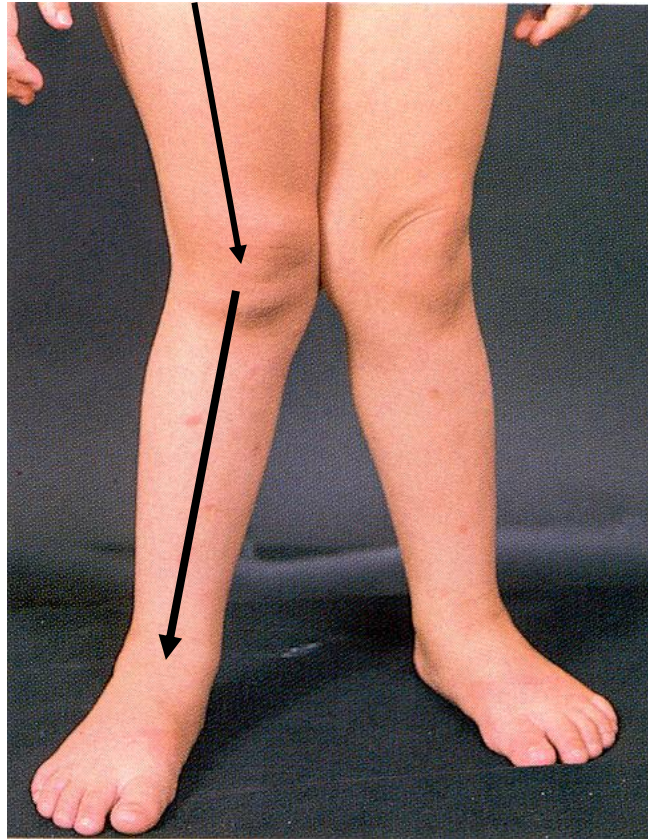
- Innominate Rotations, shears, flares
- Femoral head/neck
 - Anteversion = IR
 - Retroversion = ER
- Tibial
 - Intorsion
 - Extorsion
 - Valgus
 - Varum



- Foot
 - Rearfoot
 - Midfoot
 - Forefoot
- Dynamic assessment of foot
- Static assessment of joint gliding/mobility
- Standing
- Gait
- Running
- Relaxed
- Sleeping

Genu Valgus– weight bearing

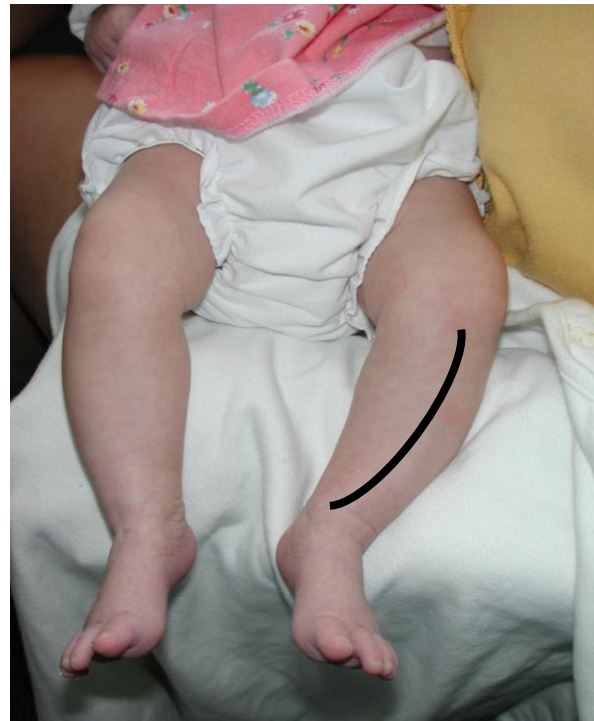- Pes Planus
- Rearfoot position
- Crural, Femoral torsions



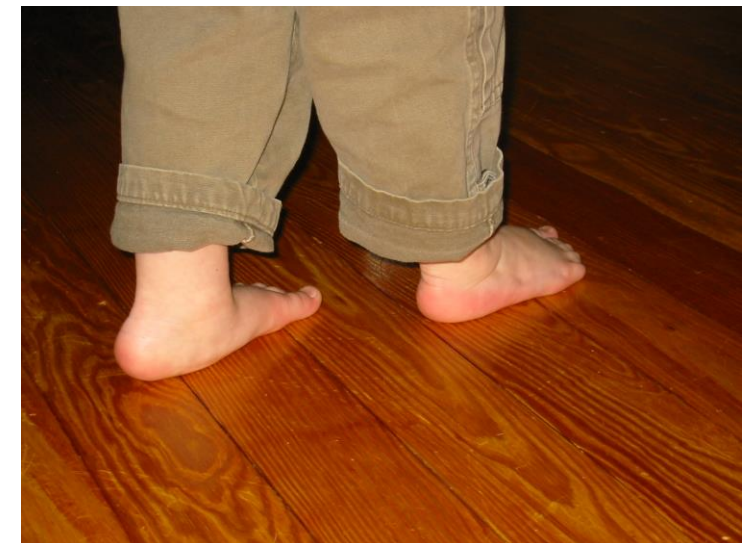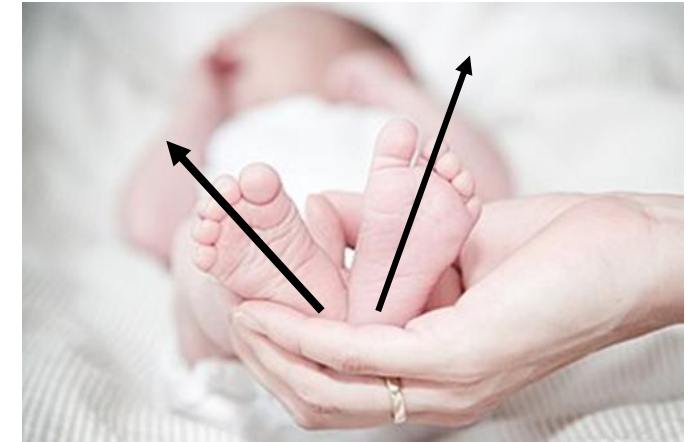Clinical Pediatrics Fig. 21.81

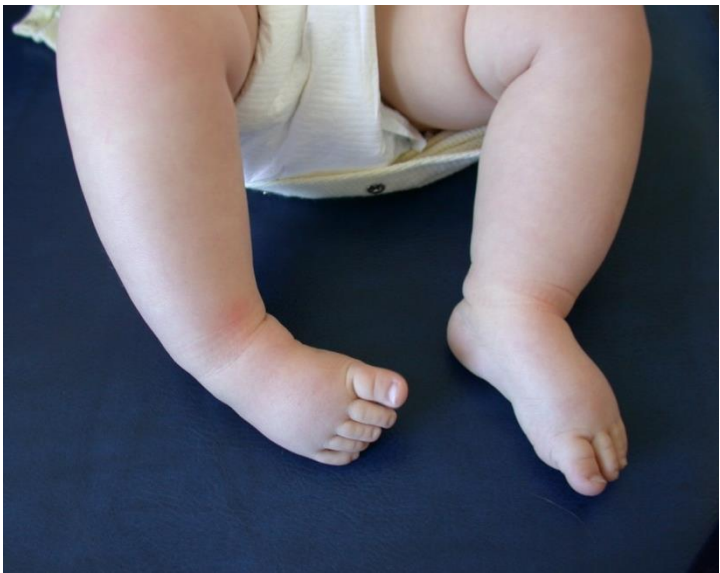Genu Varus – babies

- Pes Cavus
- Tibial intraosseous strain
- Proximal tibia, growth-plate strain

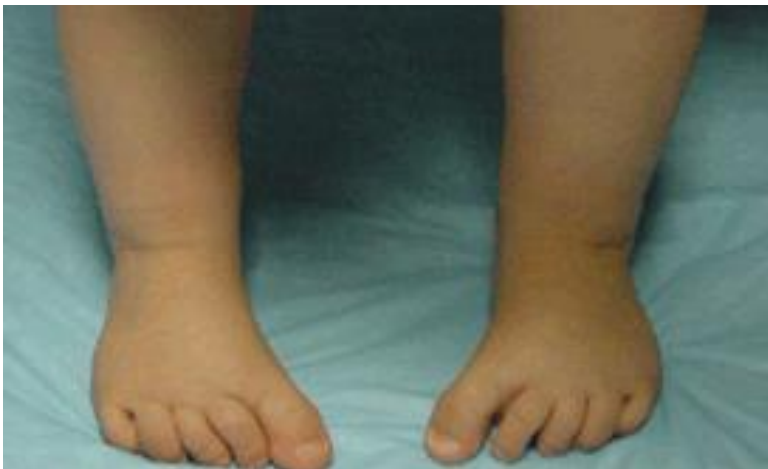

Carreiro, J; An Osteopathic Approach to Children, 2nd ed. Elsevier, Philadelphia, 2009.

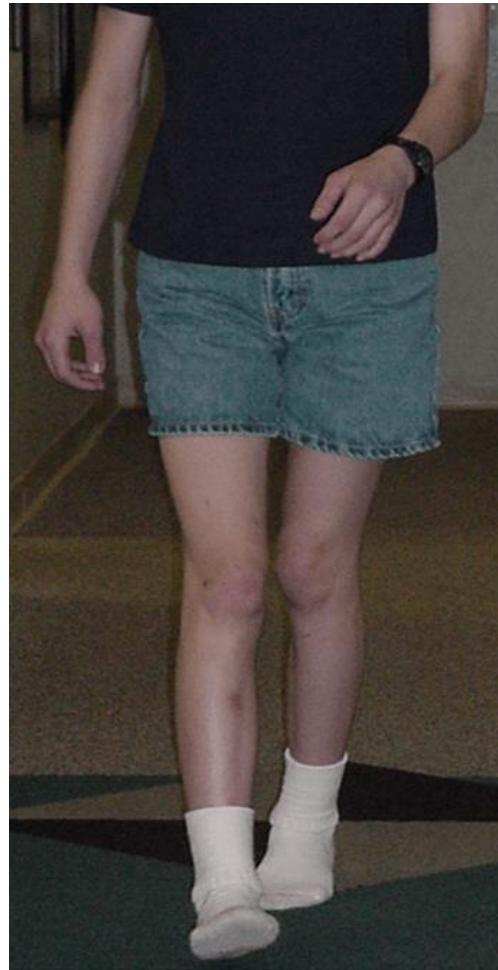



Right Tibial Varum and Forefoot ADDuctus

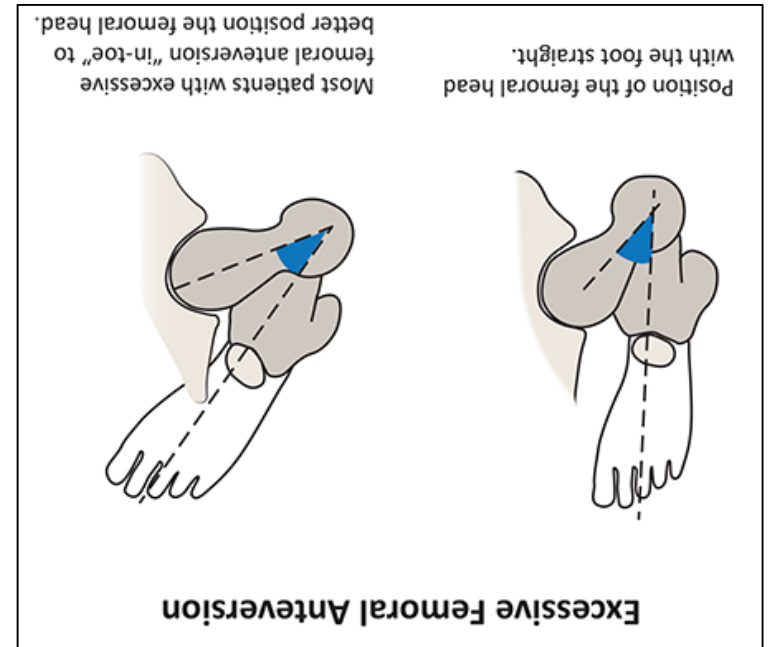


Forefoot ADDuctus

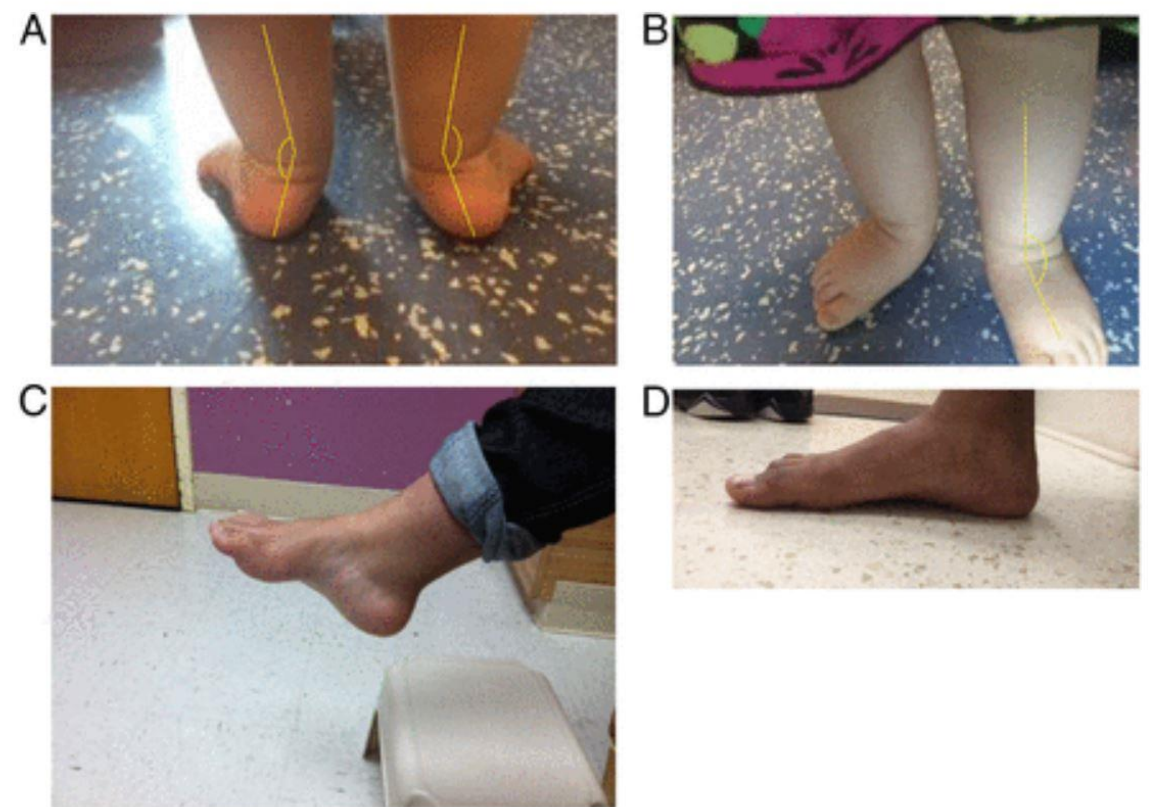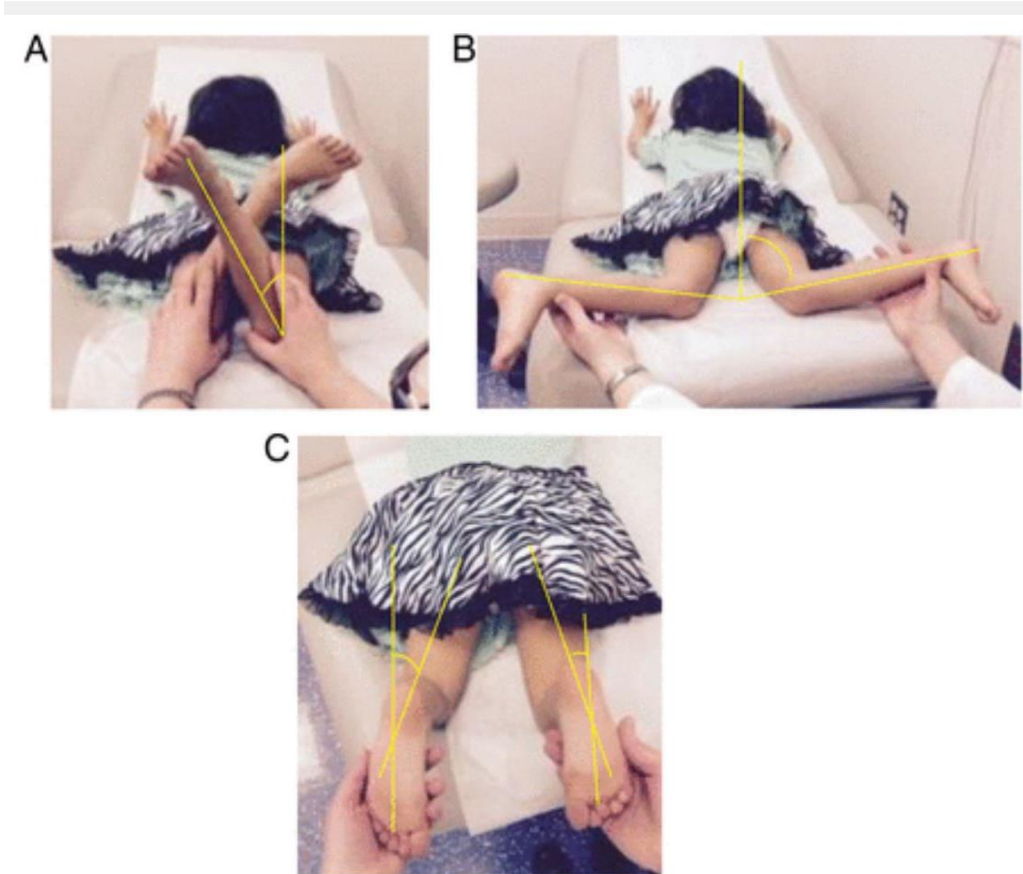


Bilateral Femoral Anteversion
Notice the feet crossing the midline

Carreiro, J; An Osteopathic Approach to Children, 2nd ed. Elsevier, Philadelphia, 2009.

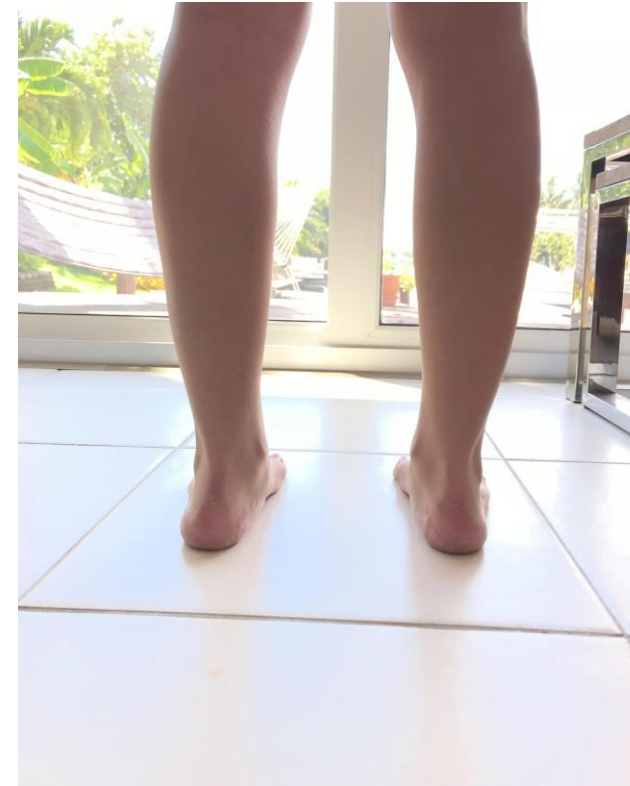
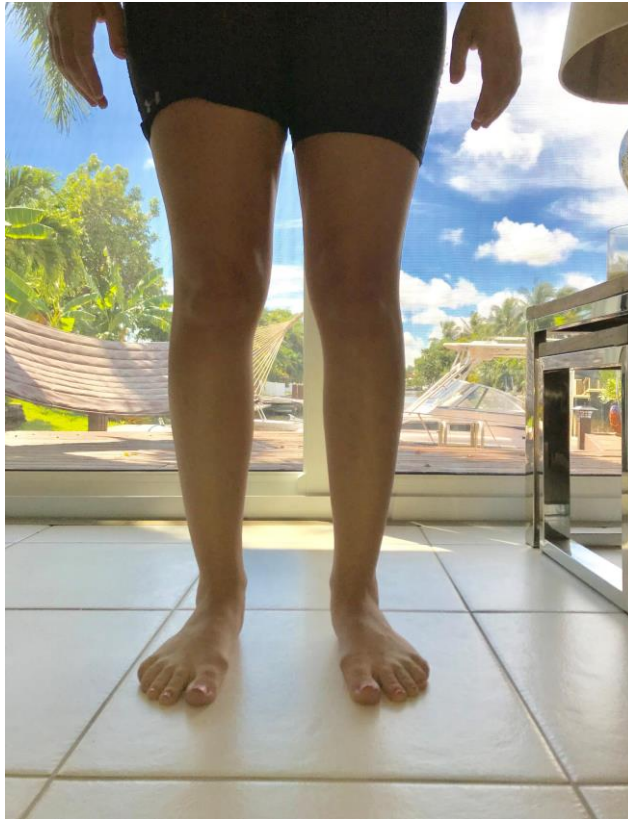
Pediatric LE Evaluation

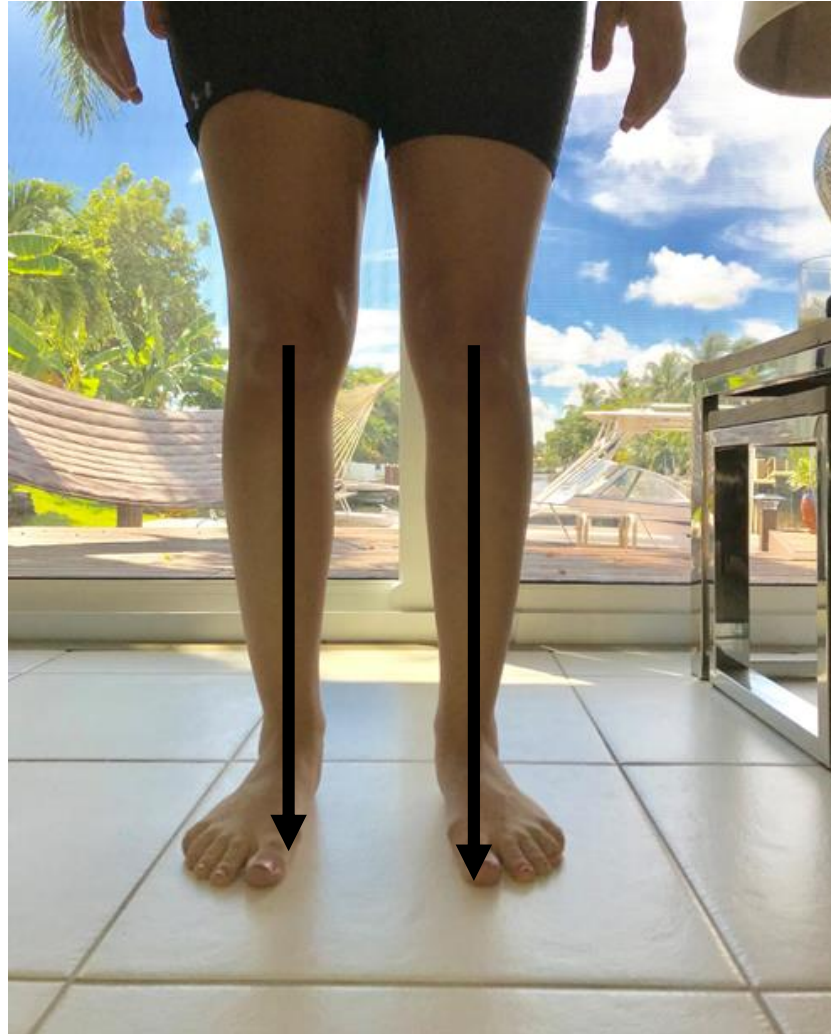



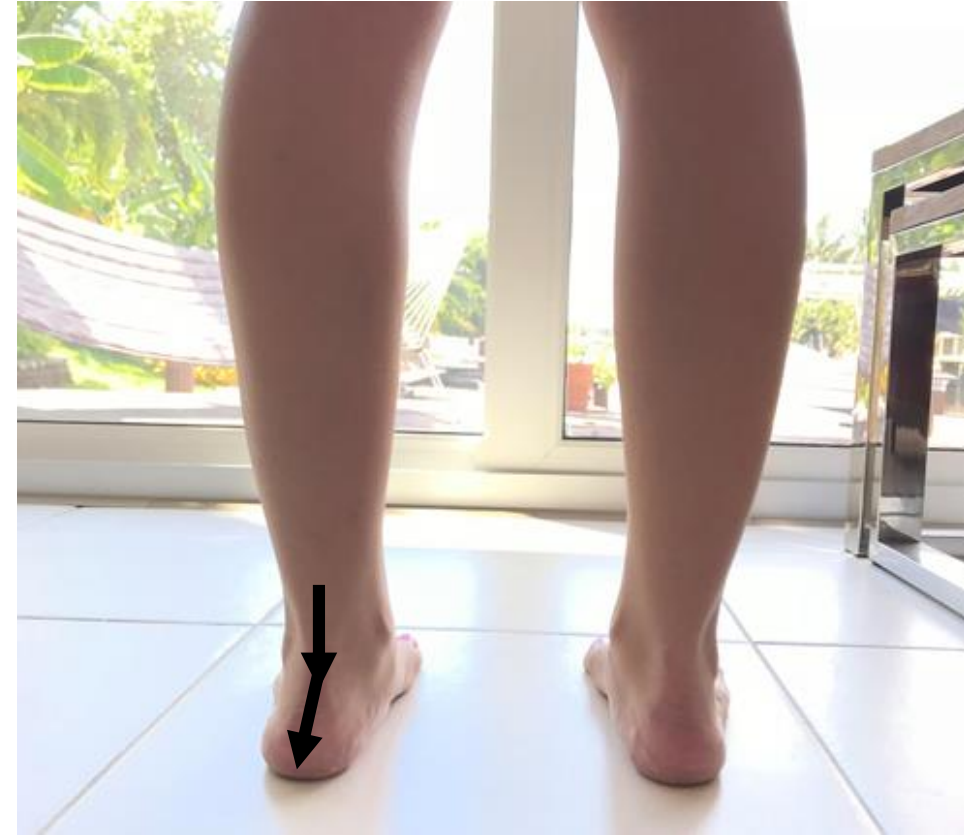Standing Posture, Alignment, 3 planes



LAB: LE Assessment of LE Alignment



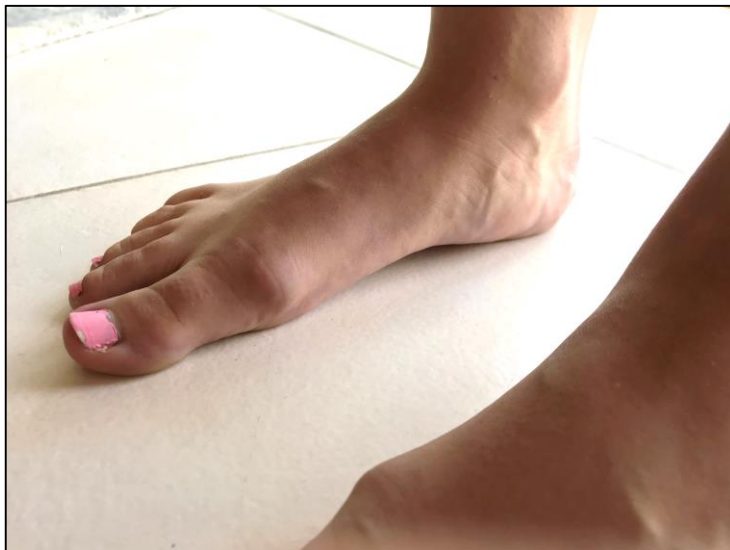Plumb line should drop from middle of patella
To between 1st and 2nd toes. Where is this
Malalignment coming from – hip or knee strain?



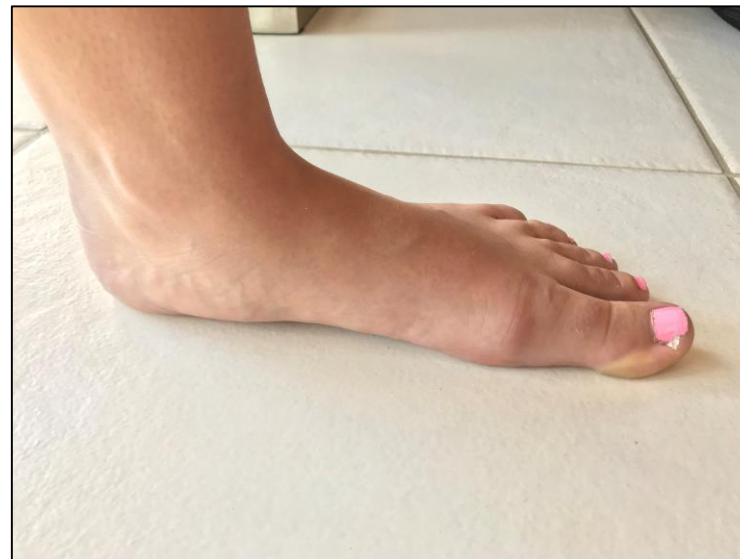With pes planus and torsions of the
femur or tibia, you will also see
malalignment of the rearfoot.
In this example: Calcaneal Valgum

Assessment of Functional vs Rigid Pes Planus

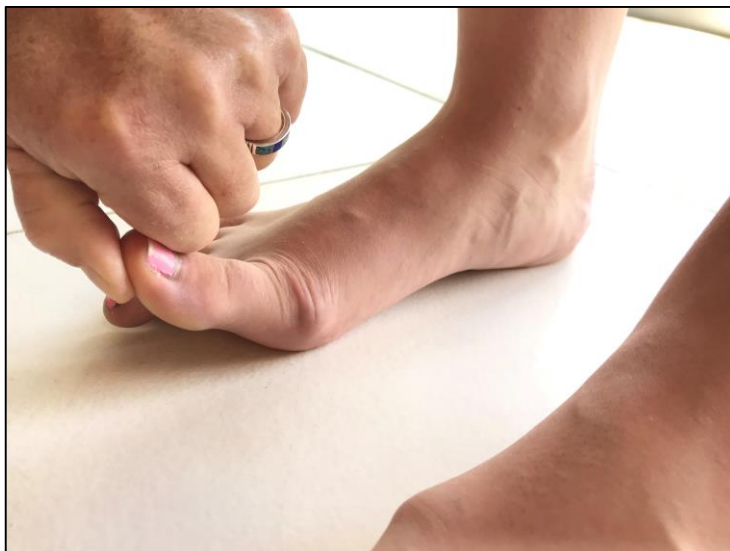Right Pes Planus



Left Pes Planus

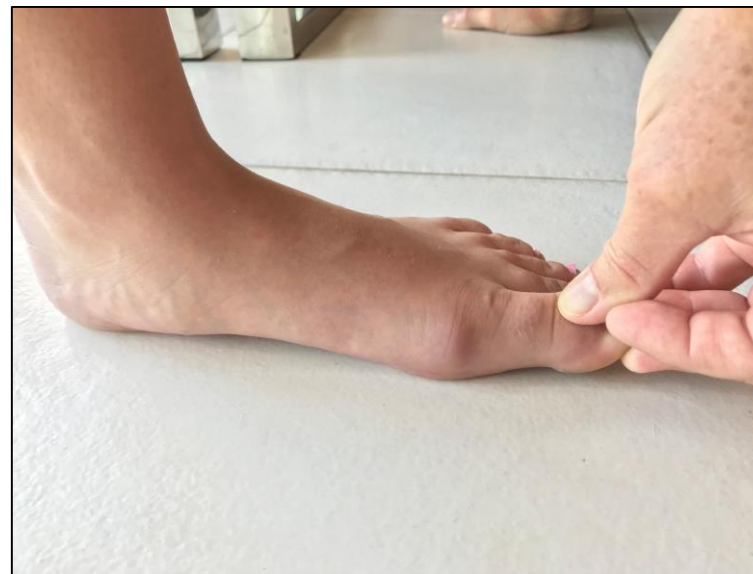

Median Arch Improves with Passive Great Toe Extension



Rigid Arch with No resolution of Median arch

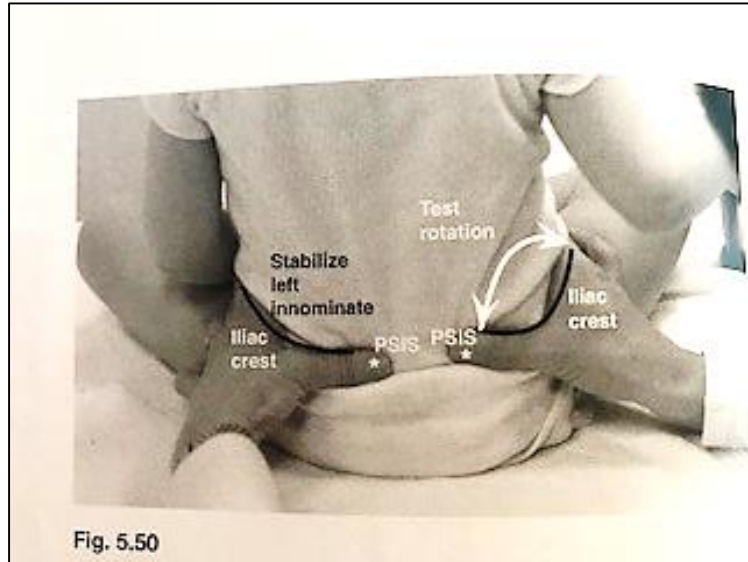
Great Toe also Rigid with passive extension



Innominate Assessment in the older child is the same as in the adult

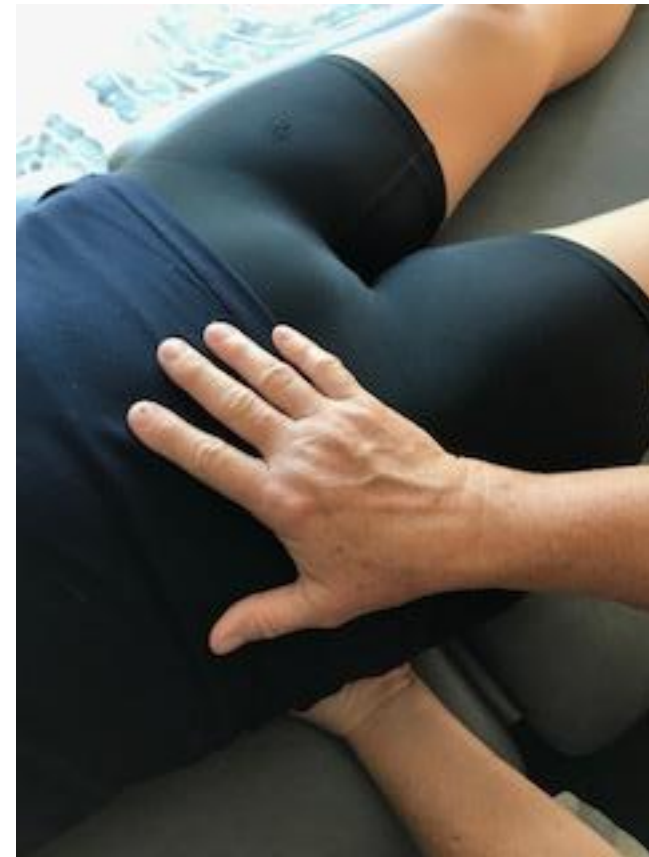- Standing:
 - Iliac crest heights
 - Greater trochanter levelness
 - Popliteal fossa levelness
 - Standing Flexion Test
 - Monitor PSIS motion during forward flexion for identifying laterality of innominate dysfunction.
 - The side that moves first or further may be the dysfunctional side
 - During forward flexion, always check for scoliosis deformity
- Seated:
 - Seated flexion test for sacral dysfunction laterality
- Supine:
 - ASIS levelness
 - Pubic symphysis levelness
 - SLR – hamstring asymmetry
- Prone:
 - PSIS levelness
 - Sacral position

Pelvis Assessment in a younger child or toddler



Seated: Stabilize one innominate
Passively motion test the opposite Innominate

- Rotations
- Shears
- Flares



Supine: For larger child, no need to stabilize
Opposite innominate during testing.
Grasp ASIS anteriorly and PSIS posteriorly
Passive motion test all planes of motion in both
Directions:

- Rotations
- Shears
- Flares

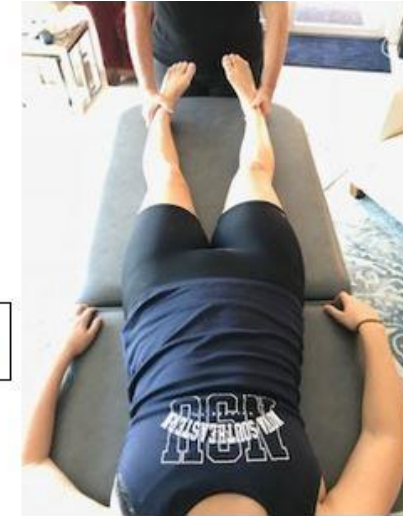
Carreiro, J. Pediatric Manual Medicine: An
Osteopathic Approach, Churchill Livingstone;
2009

Hip PROM in the supine position with the hips straight.

For younger children, observation and activity may be your main assessment of ROM.



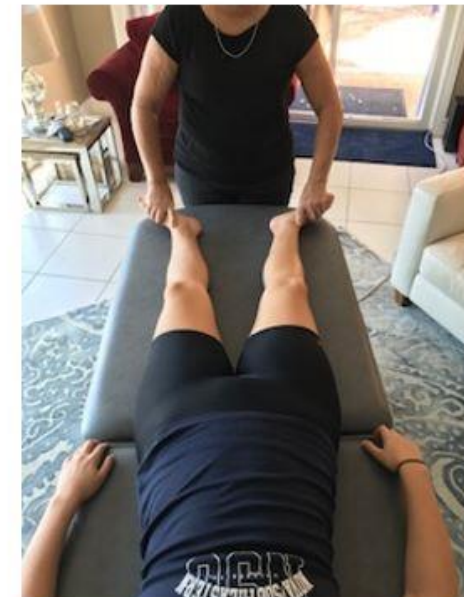ABDduction



IR

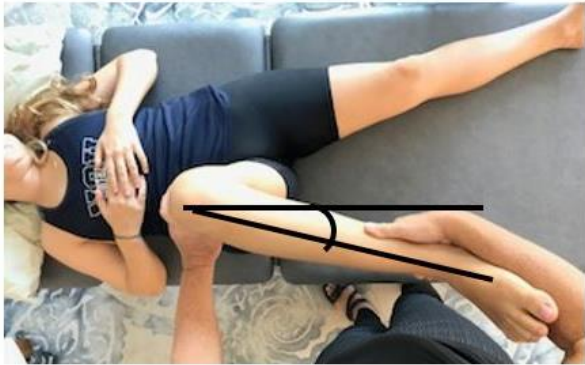

ADDuction

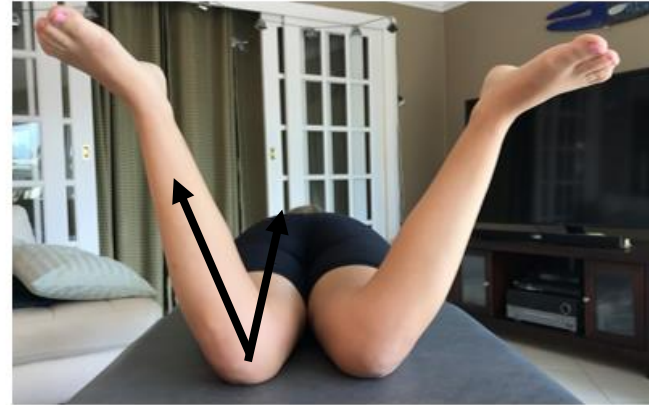


ER

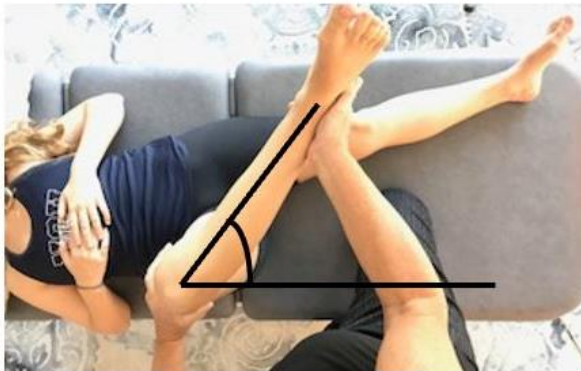
Hip ROM – Hip flexed (supine or prone)



Hip IR limited to
20 or 25 deg



Hip IR less than 45 deg

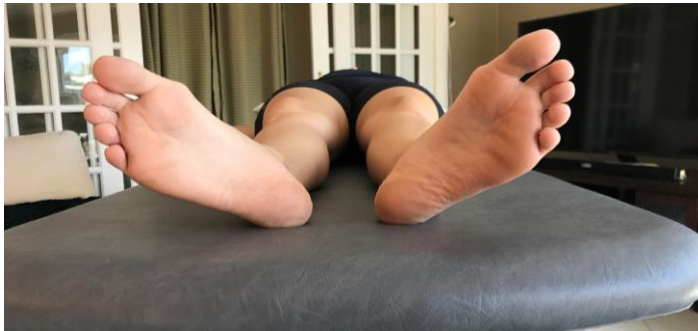

Hip ER increased
To over 45 degrees

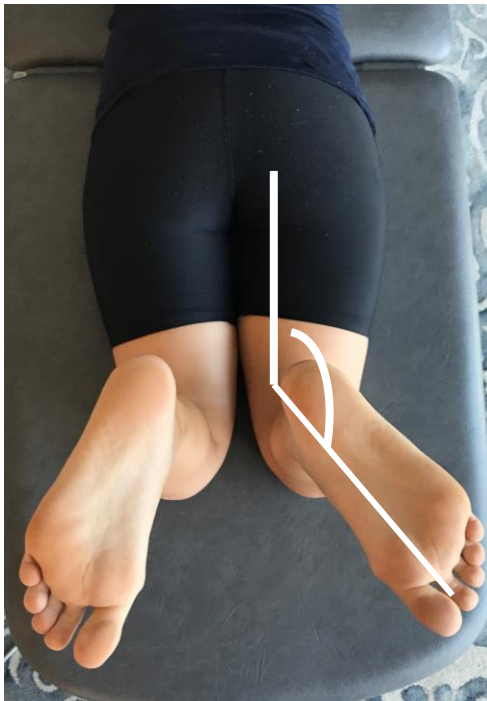

Hip ER greater than 45 deg

In infants and children – supine observation and prone hip ROM – hip vs tibial torsion




Supine Femoral Neck
Ante or Retroversion



Prone knees flexed:
Tibial Torsion

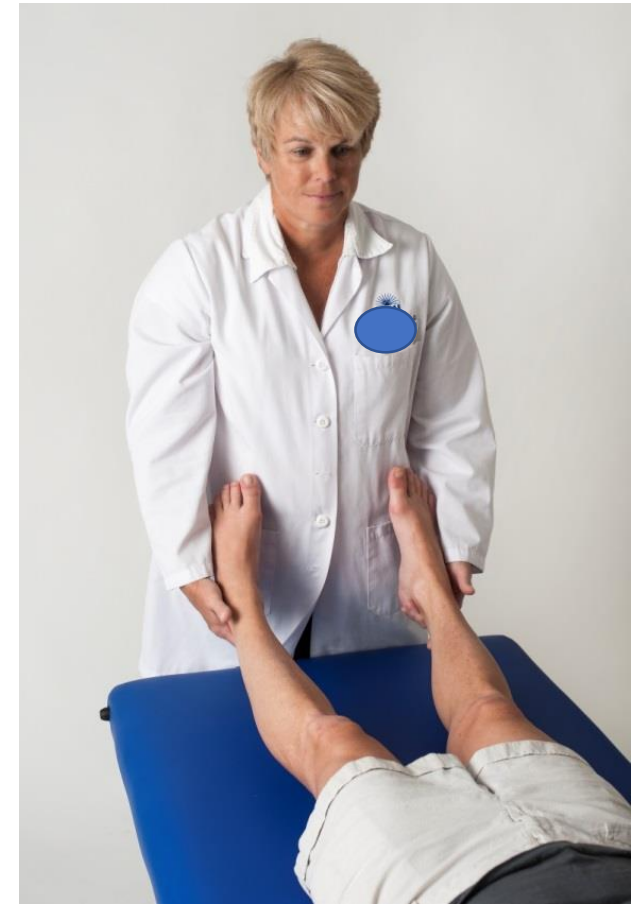
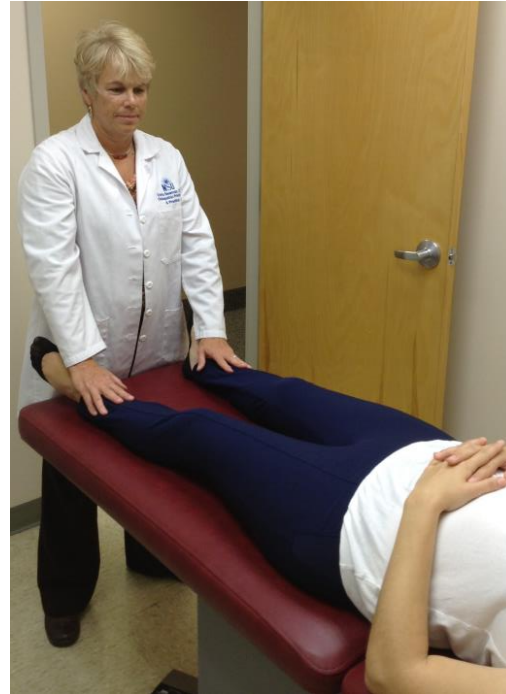
- Increased angle =
Tibial ER
- Decreased angle =
Tibial Neutral or IR

HELPS IDENTIFY FEMUR
VS TIBIAL MALALIGNMENT

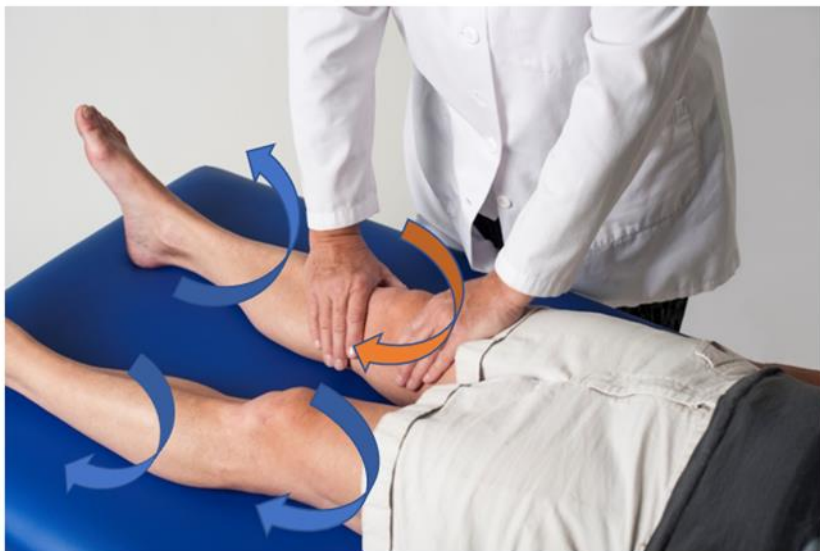
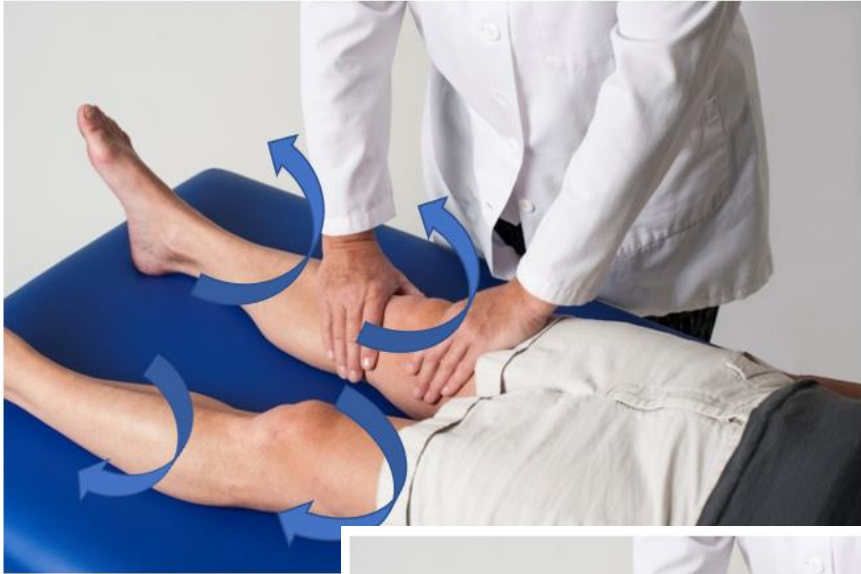
Supine evaluation of the Lower Extremities - CRI

- Lightly place your hands over the patient's ankles to evaluate the cranial rhythm in the lower extremities;
 - paired bones
 - internal and external rotation
- Cranial rhythmic impulse
 - 10-14 cycles per minute
- Identify asymmetries



To gather more information about the long bones, assess above and below the knees.



- Place your hand above and below one then the other knee
- The paired extremities should move into ER (inhalation phase) and IR (exhalation phase) in unison
- All 4 long bones should be in sync
- Identify “which of these 4 segments does not match the other”
- If a femur is “out of sync” strain is above the LE (hip, pelvic, etc)
- If a tibia is “out of sync” strain might be in the knee

Hands-on practice session

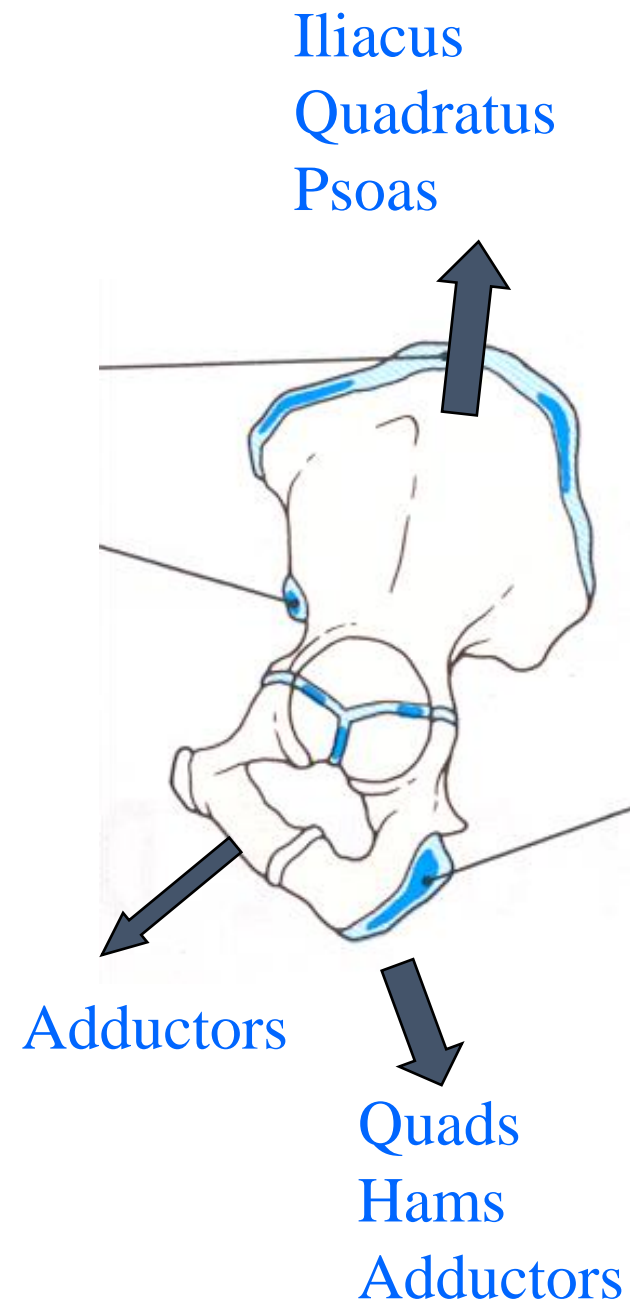
- Assessment of the pelvis and LE
 - Standing:
 - 3 planes
 - Femur alignment
 - Tibia alignment
 - Median arch – functional vs rigid pes planus
 - Seated:
 - Hip rotation
 - Prone:
 - Hip rotation with knees flexed
 - View alignment of tibia from bottom of feet with knees bent
 - Supine:
 - Tissue texture and hip rotation ROM with hips/knees extended and flexed
- Diagnose:
 - Innominate diagnosis
 - Rotations
 - Shears
 - Flares
 - Femur vs Tibial torsions
 - Median Arches
 - Fixed vs Functional Pes Planus
 - Rearfoot alignment

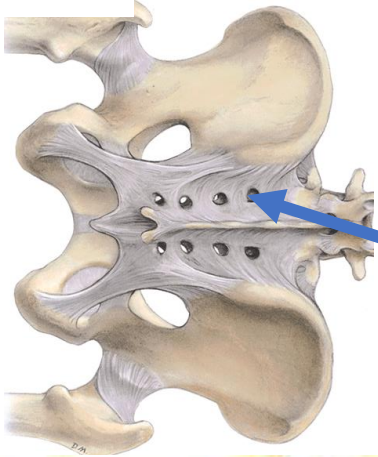
OMT Pelvis and Hip

- SI articulatory technique
- Tenderpoints
 - Psoas
 - Piriformis
 - Hip Adductors
- BLT
 - Innominate
 - Ilium
 - Ischium
 - Pubis
 - All meet at the acetabulum

Ossification of Pelvis & LE

- Innominate – 20 yrs
 - 3 parts (ilium, ischium, pubes)
 - All forces resolve at the cartilaginous acetabulum
 - Interosseous strains in the pelvis and acetabulum can alter gait
- Femur – 16-19yrs
- Tibia/Fibula – 16-19yrs
- Foot/Ankle-14-20yrs





Generalized SIJ Articulatory Technique

General articulatory technique for the SI joints - bilaterally

- A. Patient in lateral recumbent position (hugging the table). Physician's posterior hand **medial to the SI joint** on the sacrum. Wedge your elbow into your side to create a stable fulcrum to articulate the joint around.
- B. Physician grasps the patient's superior leg at the knee. Compress posteriorly along the line of the femur
- C. With pressure posteriorly thru the femur, passively flex the hip, ABDuct the hip and extend the hip. "circles"
Start with small circles, move to larger circles
- D. Extend the hip. You may hear an articulation.
- E. Repeat several times. You may use this general articulatory technique as far superior as the middle lumbar spine.

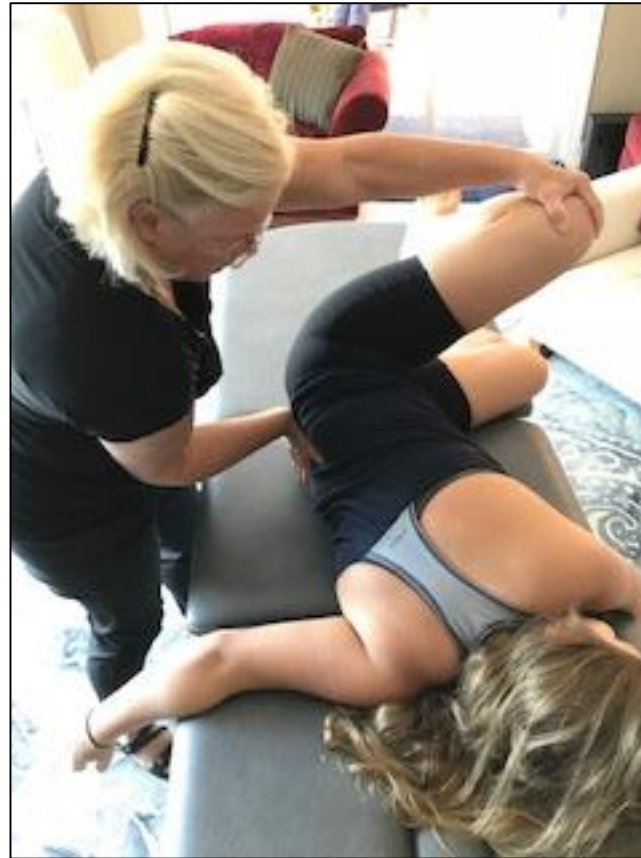

SI Articulatory – Lateral Recumbent Position

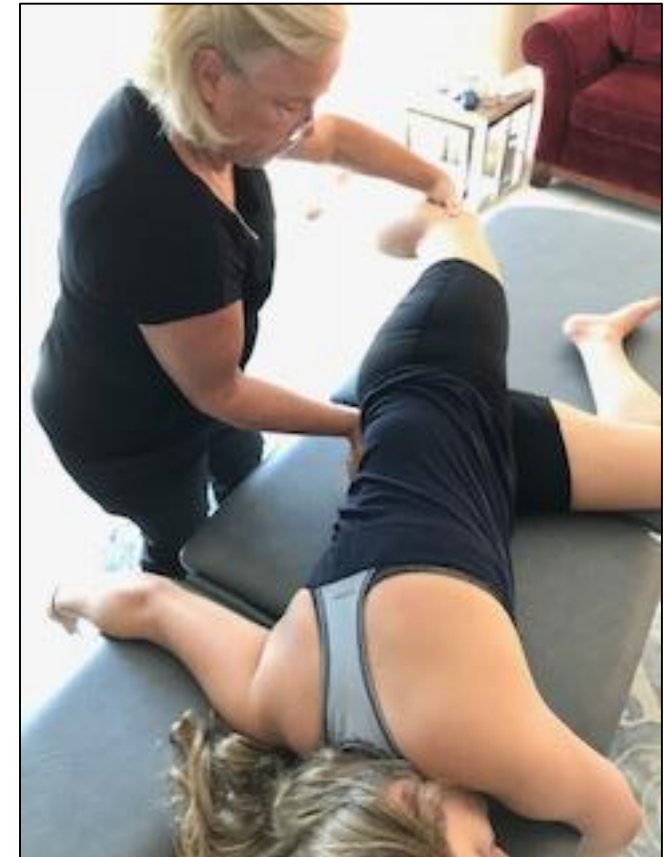Flex hip over 90 deg



ABDUCT hip

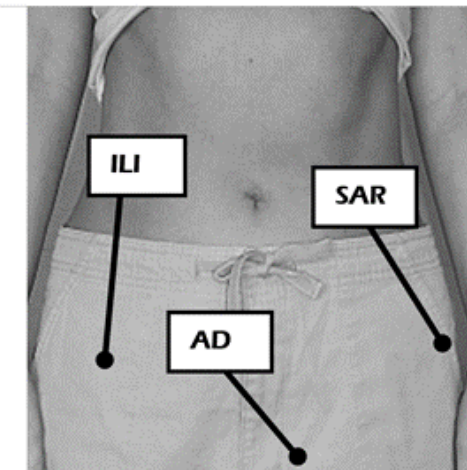
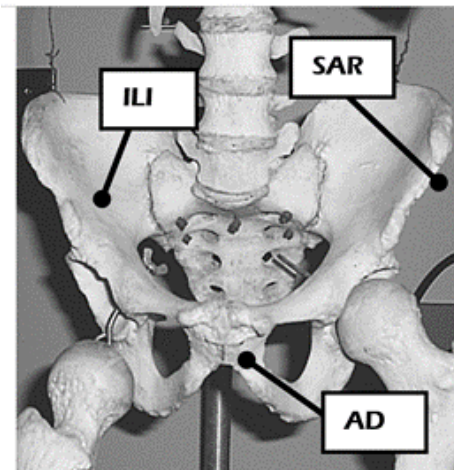
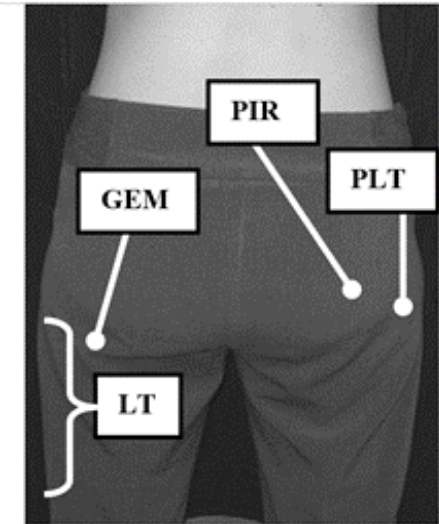
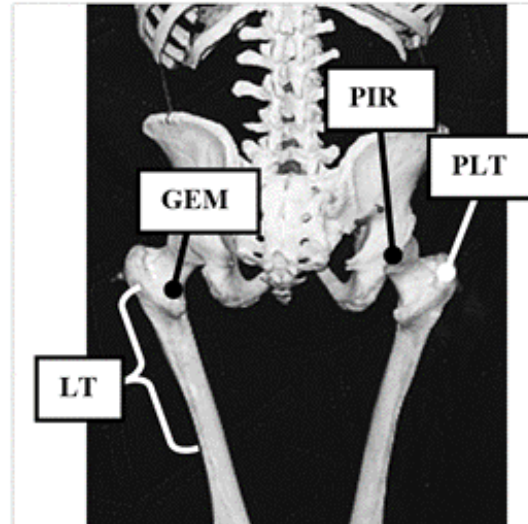


Extend hip – Repeat Procedure



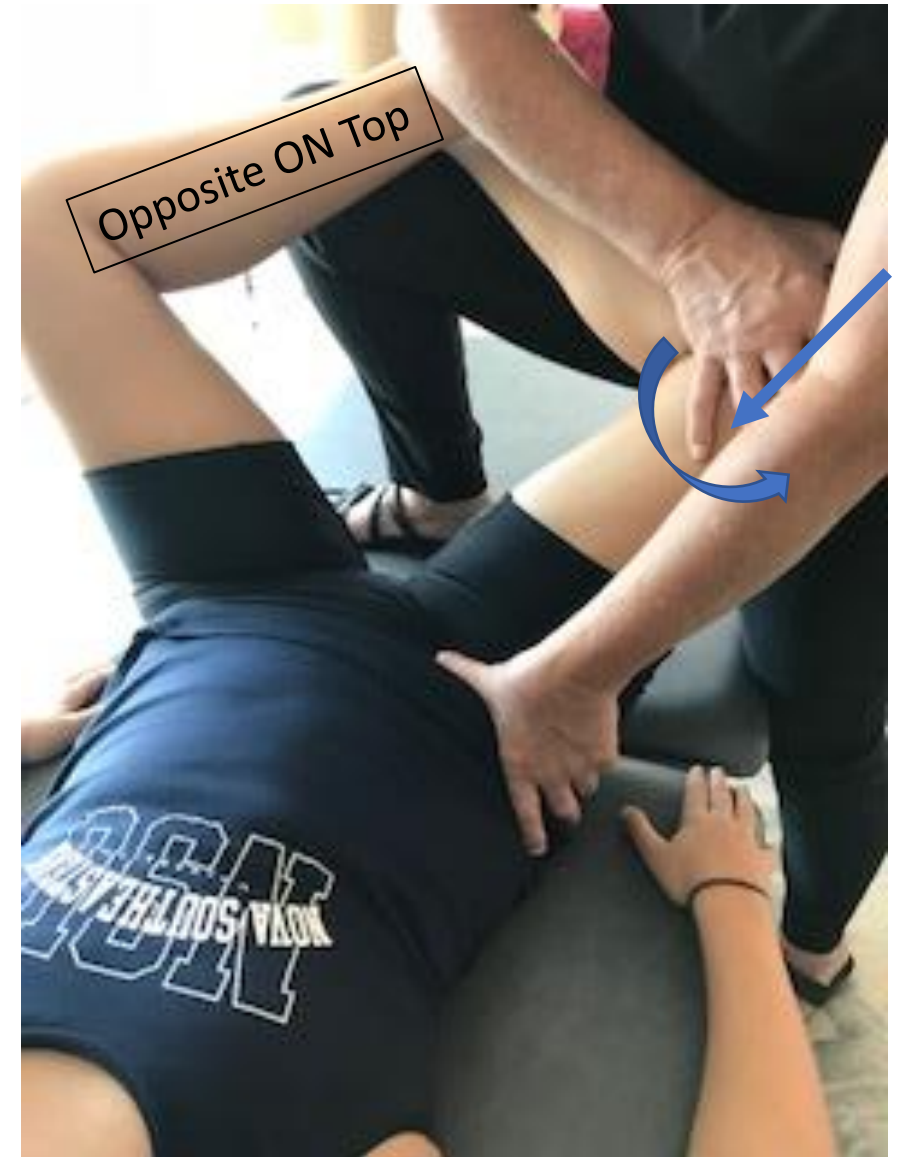Common Tenderpoints that can affect lower quadrant motion and alignment

- Iliopsoas – ILI
 - Lumbar spines to
 - Lesser trochanter of the femur
- Piriformis – PIR
 - Anterior sacrum to
 - Top of greater trochanter of the femur
- Hip Adductors – AD
 - Pubic ramus to
 - Medial femur



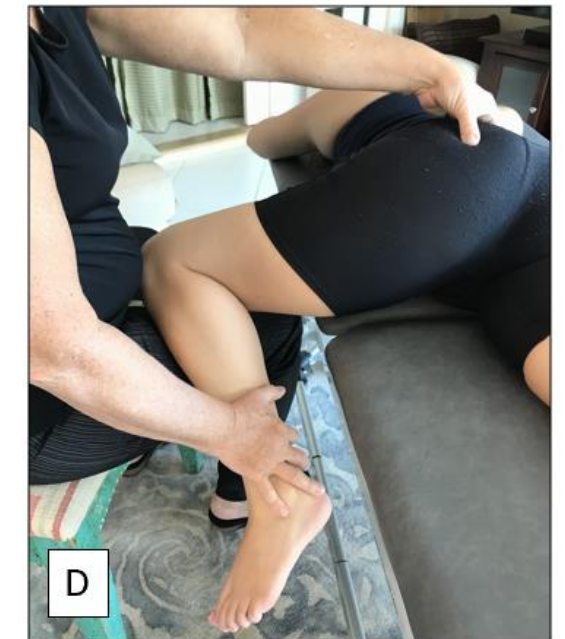
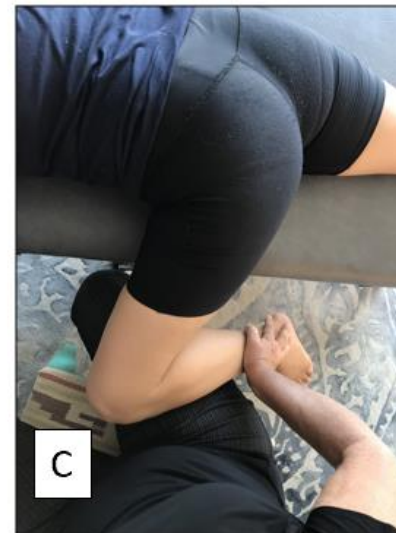
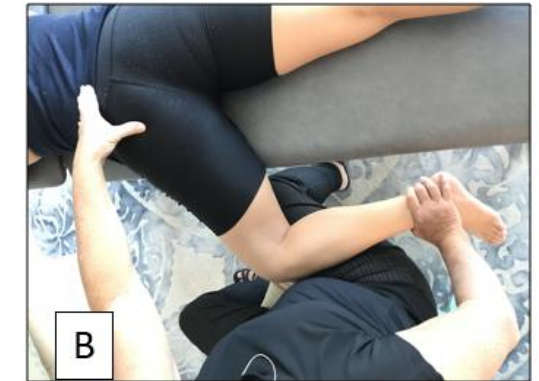
Counterstrain Treatment Position: Left Iliopsoas

- Patient supine
- Locate tenderpoint just medial and inferior to ipsilateral ASIS
- Physician stand same side of tenderpoint
- Place patient's ankles on your thigh; opposite ankle on top
- Allow patient's knee to move apart externally rotating the hip and bringing the distal muscle attachment towards the proximal
- Flex & ER the hips until the tenderpoint improves 70%
- Add inhibitory muscle force by “leaning” into the femur with your torso
- After 90 seconds, **PASSIVELY** return the patient's legs to the table



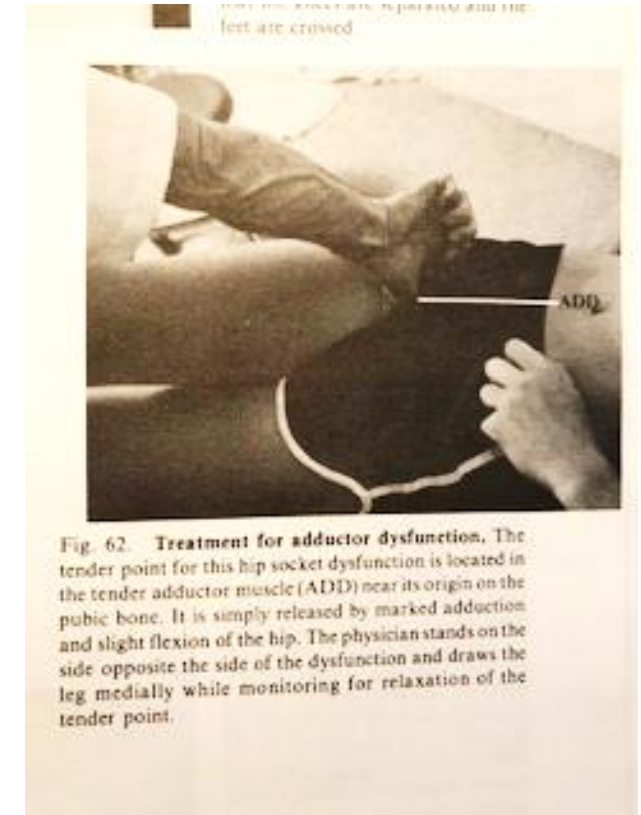
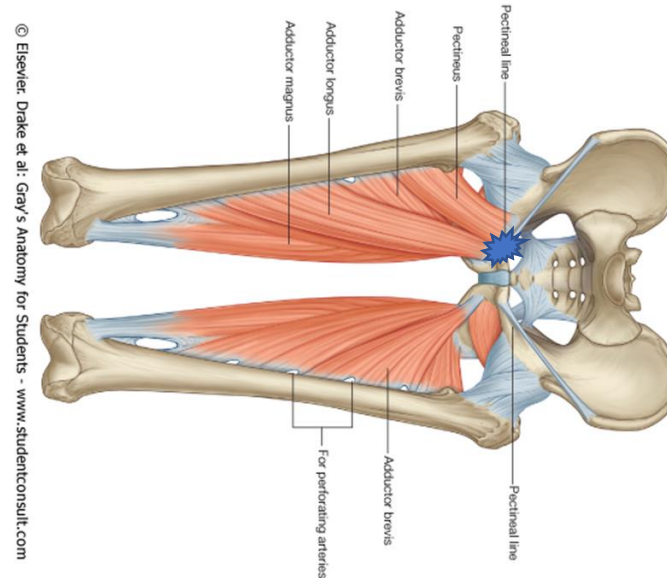
Counterstrain Tx for Left Piriformis Tenderpoint

- A) Patient prone close to the edge of the table
 - Identify the tenderpoint: $\frac{1}{2}$ way between the PSIS and the greater trochanter of the femur
 - B) Physician seated on a rolling stool with the ipsilateral knee on your lap; this allows hip ABDuction
 - C) Push the patient's lower leg down causing hip ER
 - D) Flex the hip 135 degrees by rolling stool towards patient's head
 - Fine tune with IR and ER to achieve 70% decrease in pain
- Hold 90 seconds
 - PASSIVE return



Counterstrain for “Hip Socket Dysfunction”

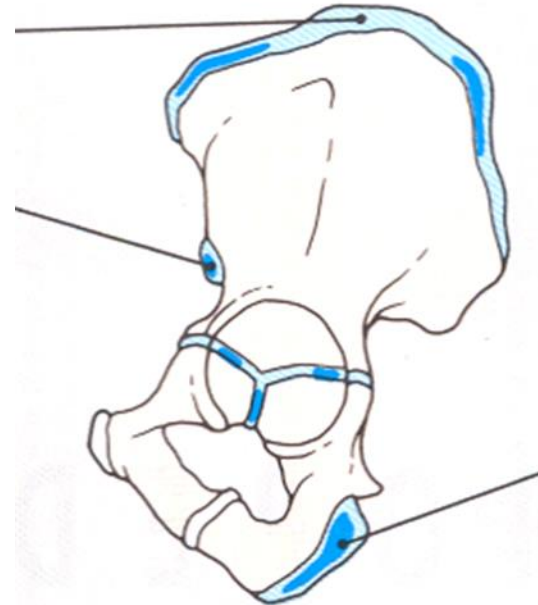
- Patient supine
- Tenderpoint on proximal attachment of the ADDuctor muscles
- Stand on the contralateral side of the tenderpoint to be treated
 - ADDuct (slight flex or IR)
- Obtain 70% improvement in pain when the point is pressed
- Hold 90 sec
- PASSIVELY return to resting position
- USE CAUTION! Warn patient!



Strain and Counterstrain
Lawrence Jones, DO

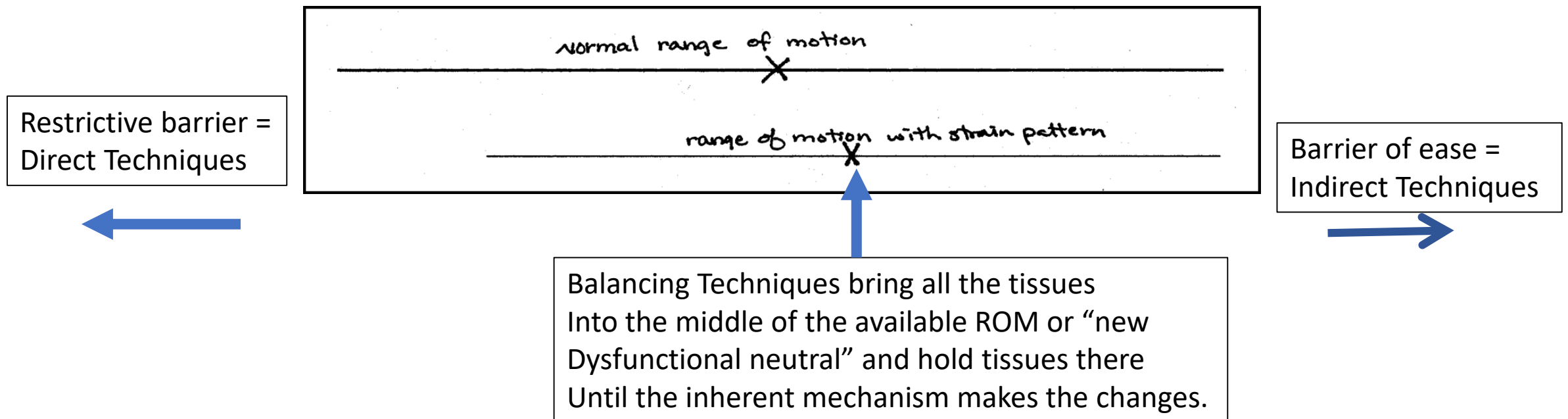
BLT Innominate

- Innominate
 - Ilium
 - Ischium
 - Pubis
 - All meet at the acetabulum
- Use distraction, traction, torsion forces to bring tissues to a neutral position, neither under tension nor slack



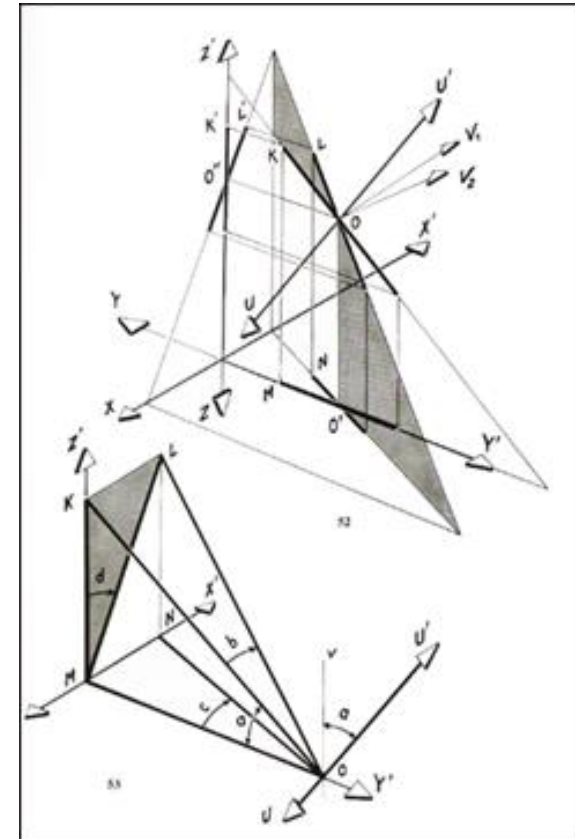
Balanced Ligamentous Technique Review

- BLT = *Engage the Neutral*
 - The “new” neutral (of the lesion) becomes a fulcrum for physiological change

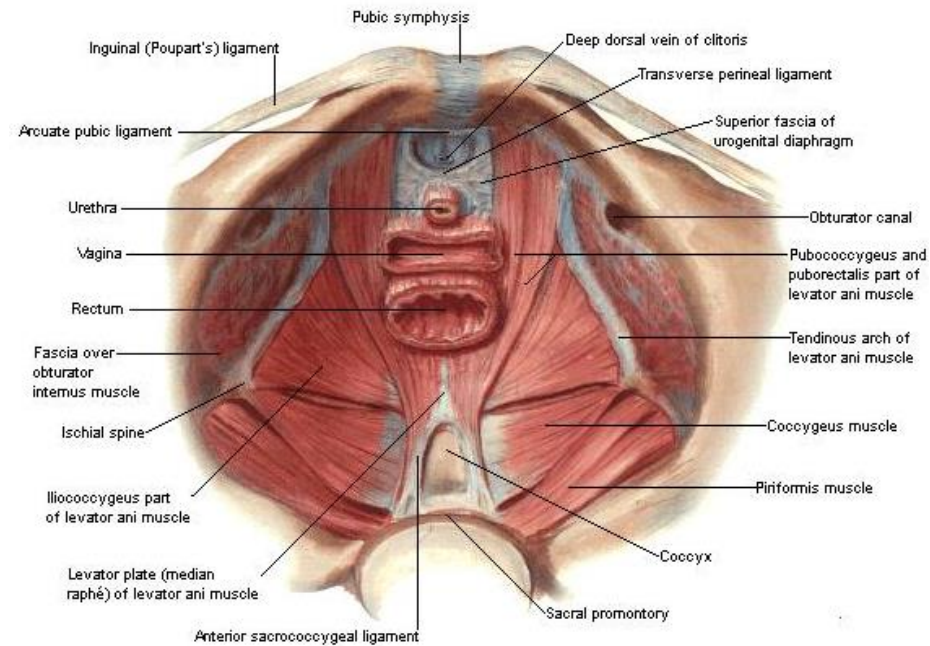
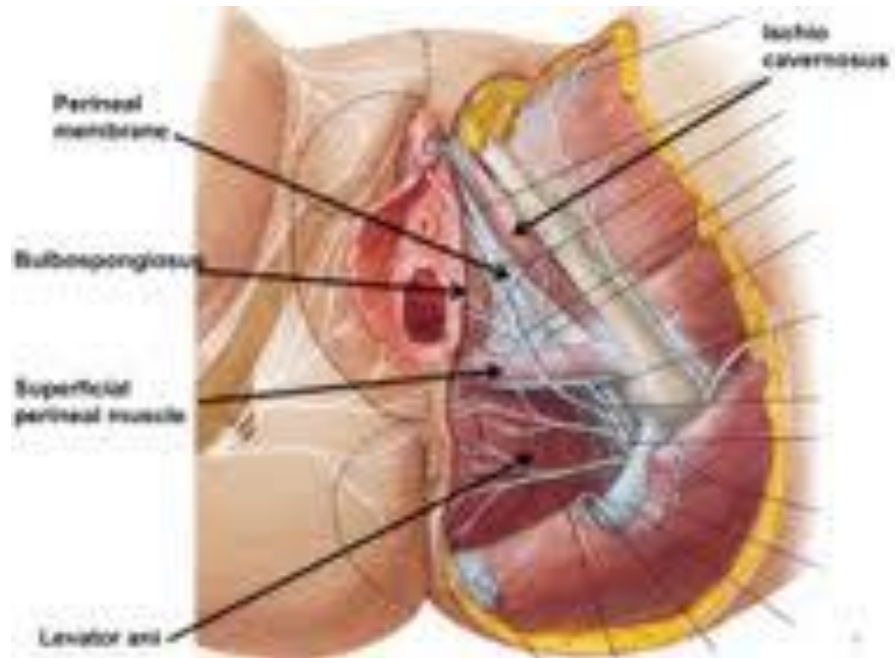
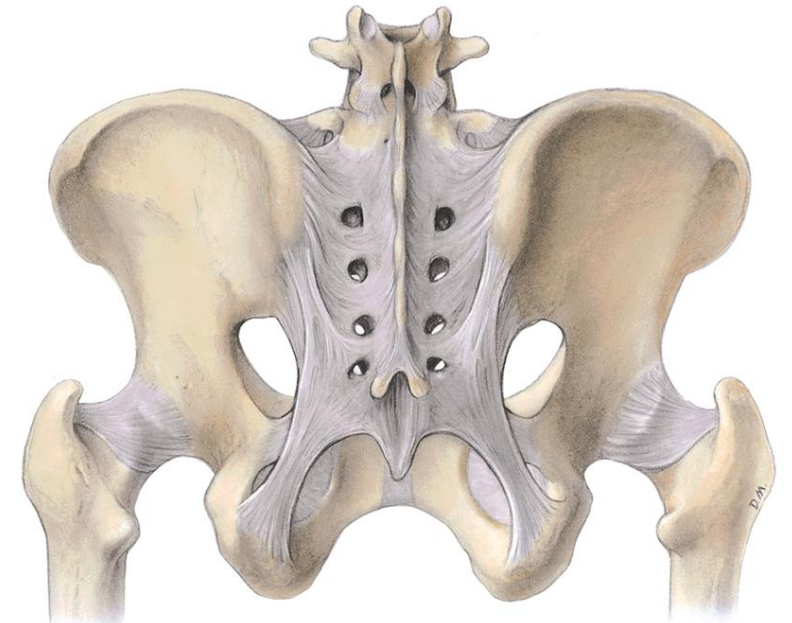
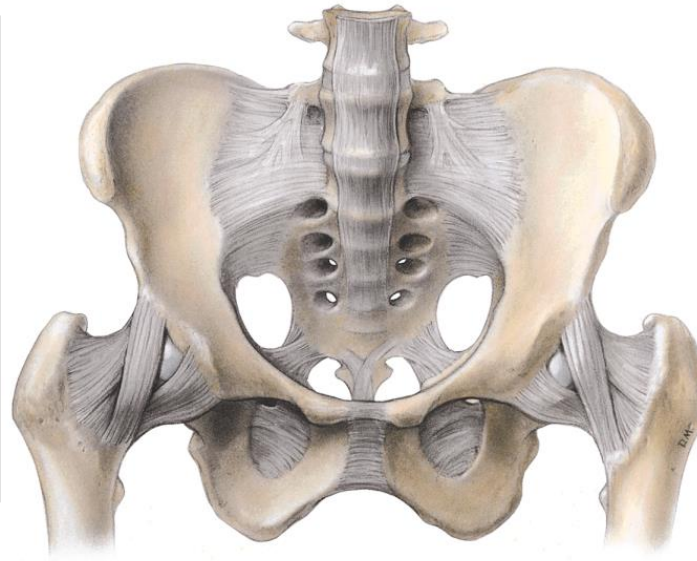


BLT - innominate

- Balancing occurs about all planes of motion
- Begin with 3 planes of motion
 - Superior/Inferior Shears
 - Inflare/Outflare
 - Anterior/Posterior Rotations
- Can also add:
 - Compression/Distraction
 - And compressions or twists within the innominate bone itself

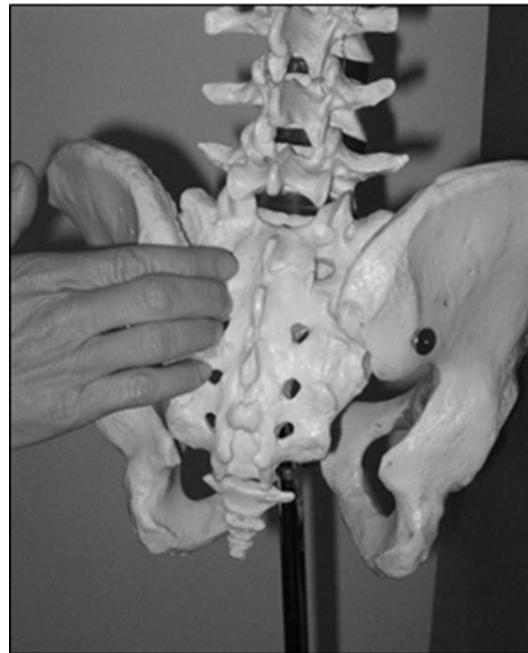
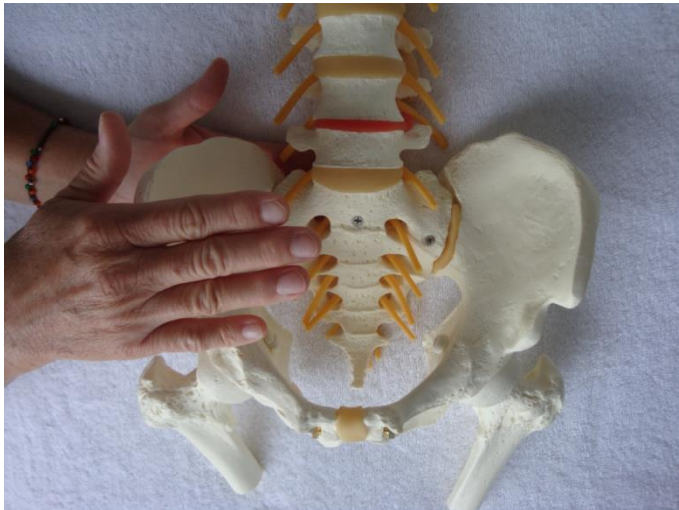


Tissues being treated during BLT of the innominate



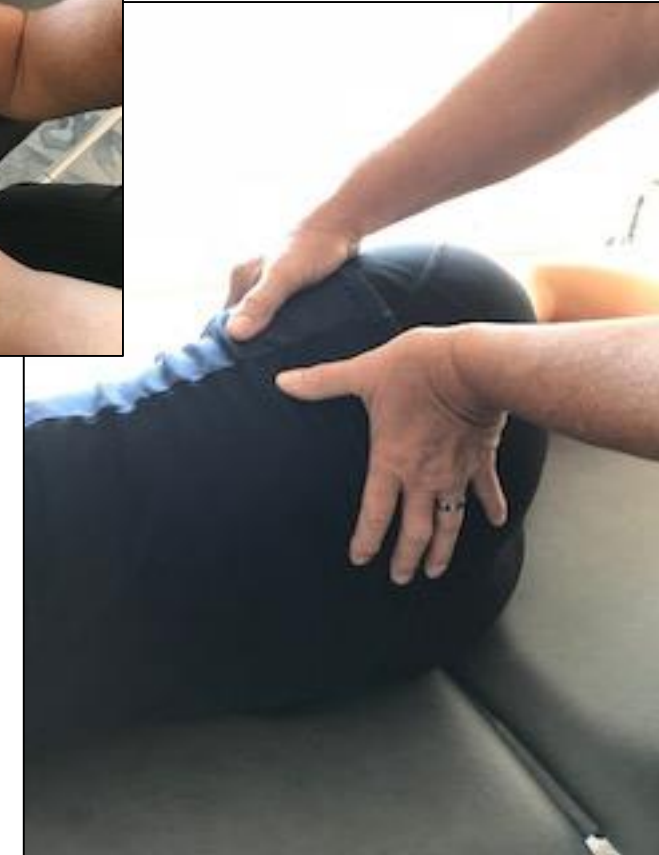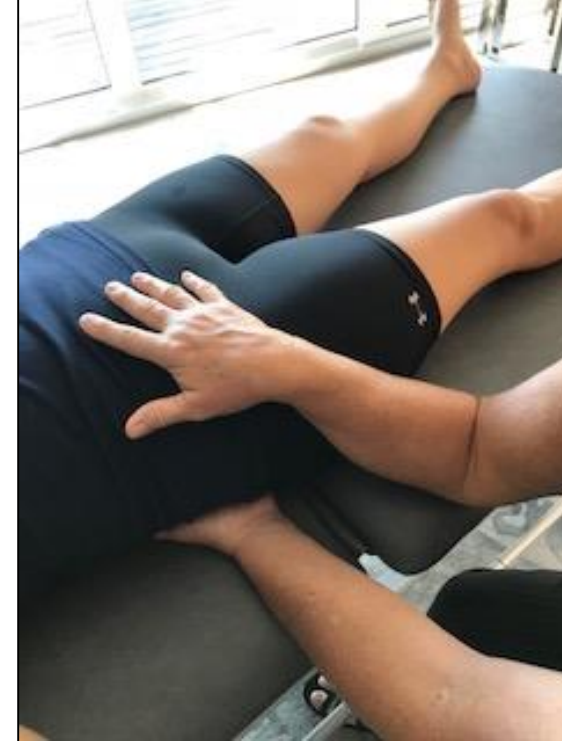
Assessment of the Innominate- Supine Technique

- Seated beside the supine patient
- Place the top hand with the palm on the ASIS
- Place the bottom hand with the fingers in the SI joint and grasping the PSIS



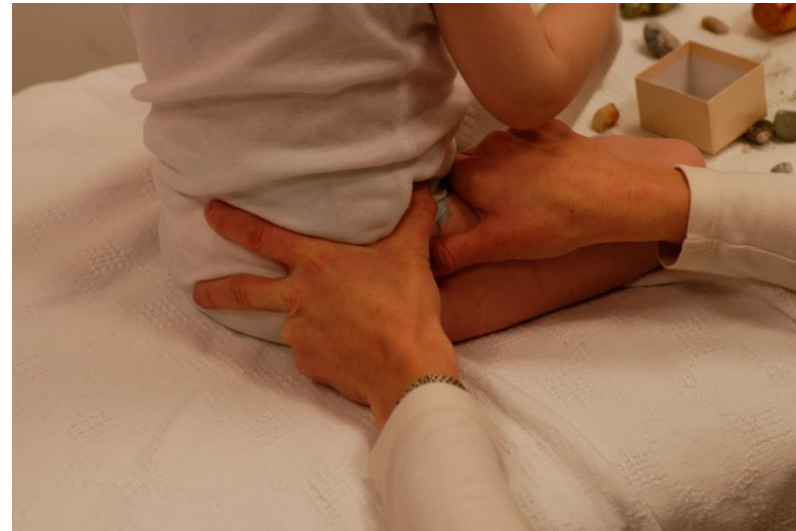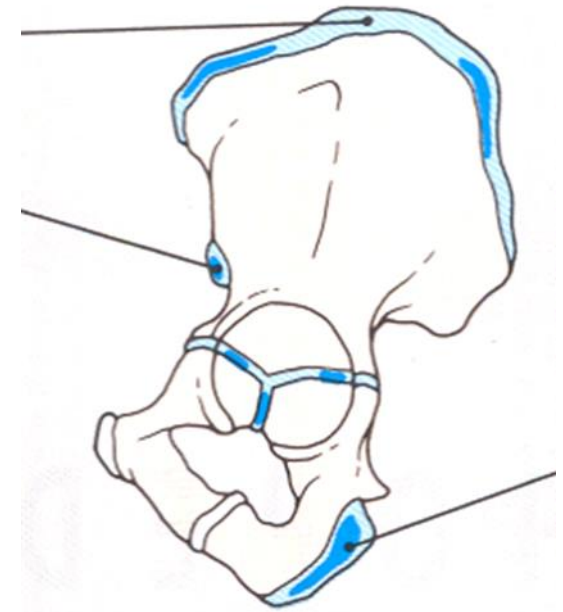
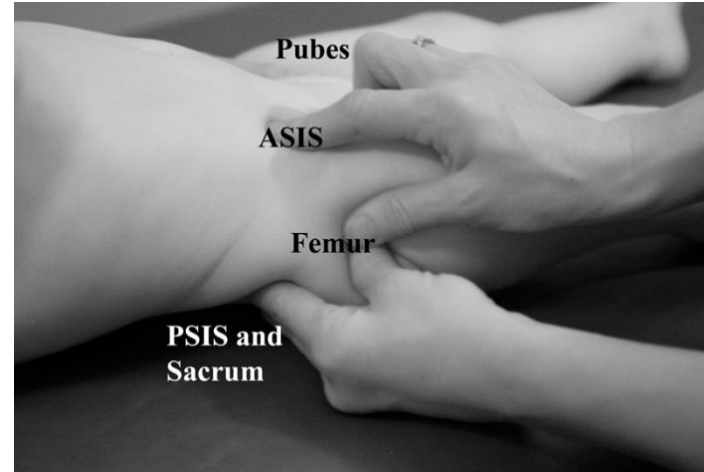
BLT Innominate - Adult

- Seated on the ipsilateral side of the supine patient
- Anterior hand is over the ASIS
- Posterior hand grasps the PSIS with fingers in the SI joint
- Motion Test all 3 planes of motion
- Stack the “middle” of the available range of motion in all 3 planes
- Wait for the inherent mechanism to make tissue texture changes
- Retest, Repeat several times



BLT of the pediatric “composite” innominate

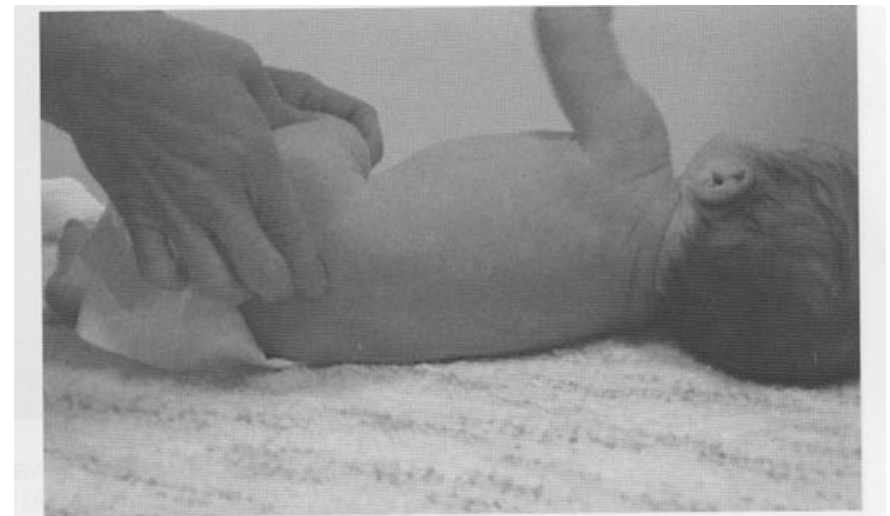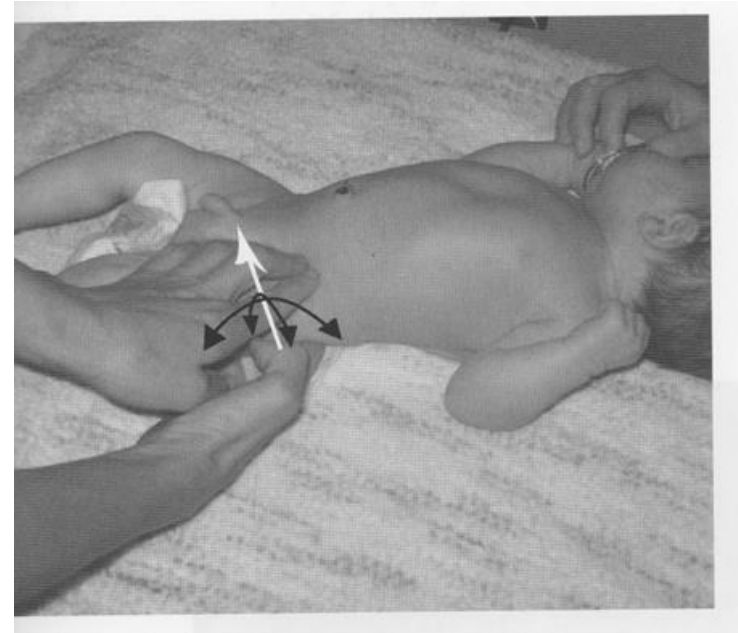- It is OK to test 3 planes of innominate motion as in adults:
 - Ant and Post Rotation
 - Superior and Inferior Shear
 - Inflare and Outflare
- However, there may be restrictions or strains between the developing parts of the bone = intraosseous strains
- This may compound the “planes of motion” that need to be treated

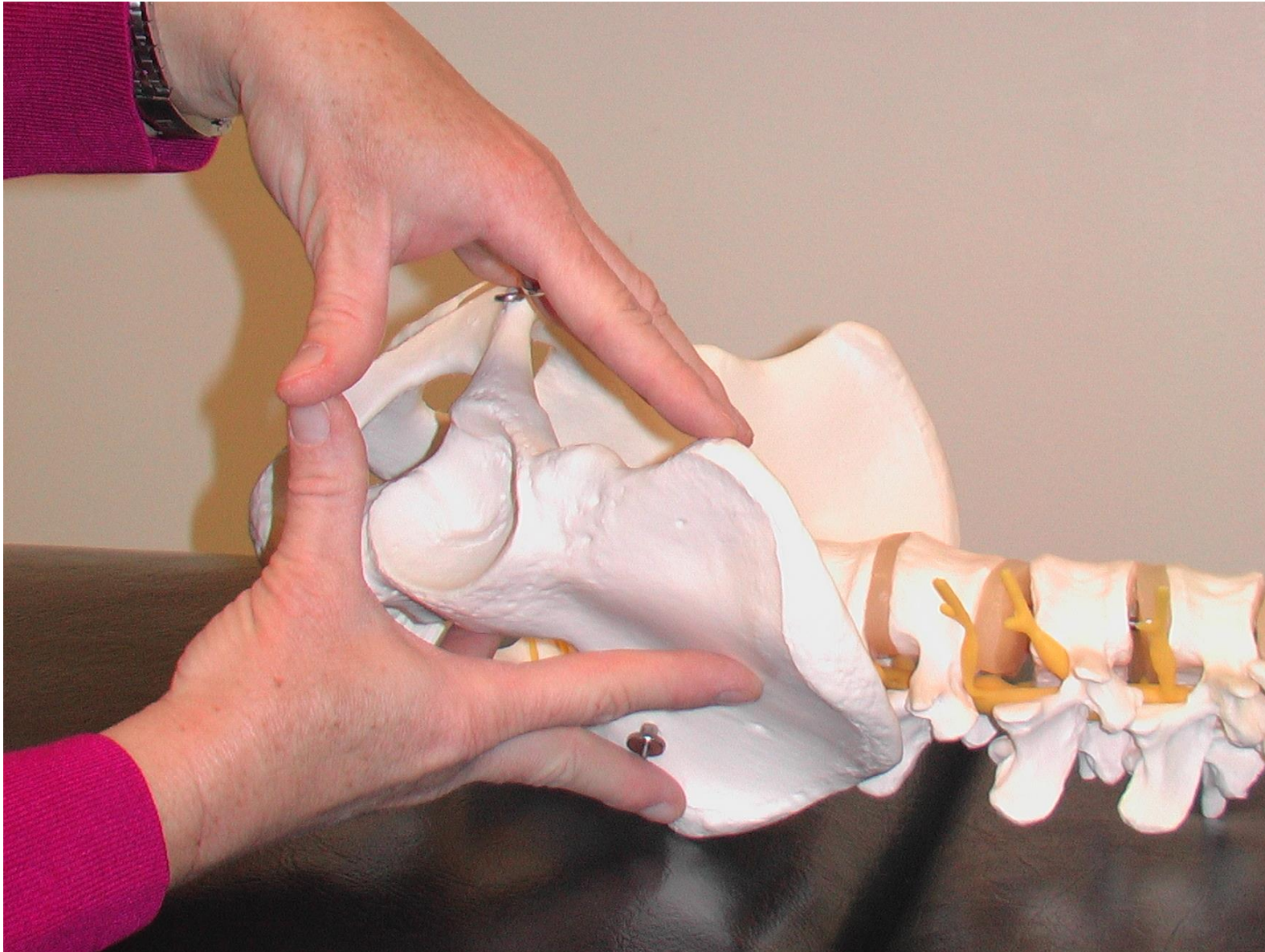


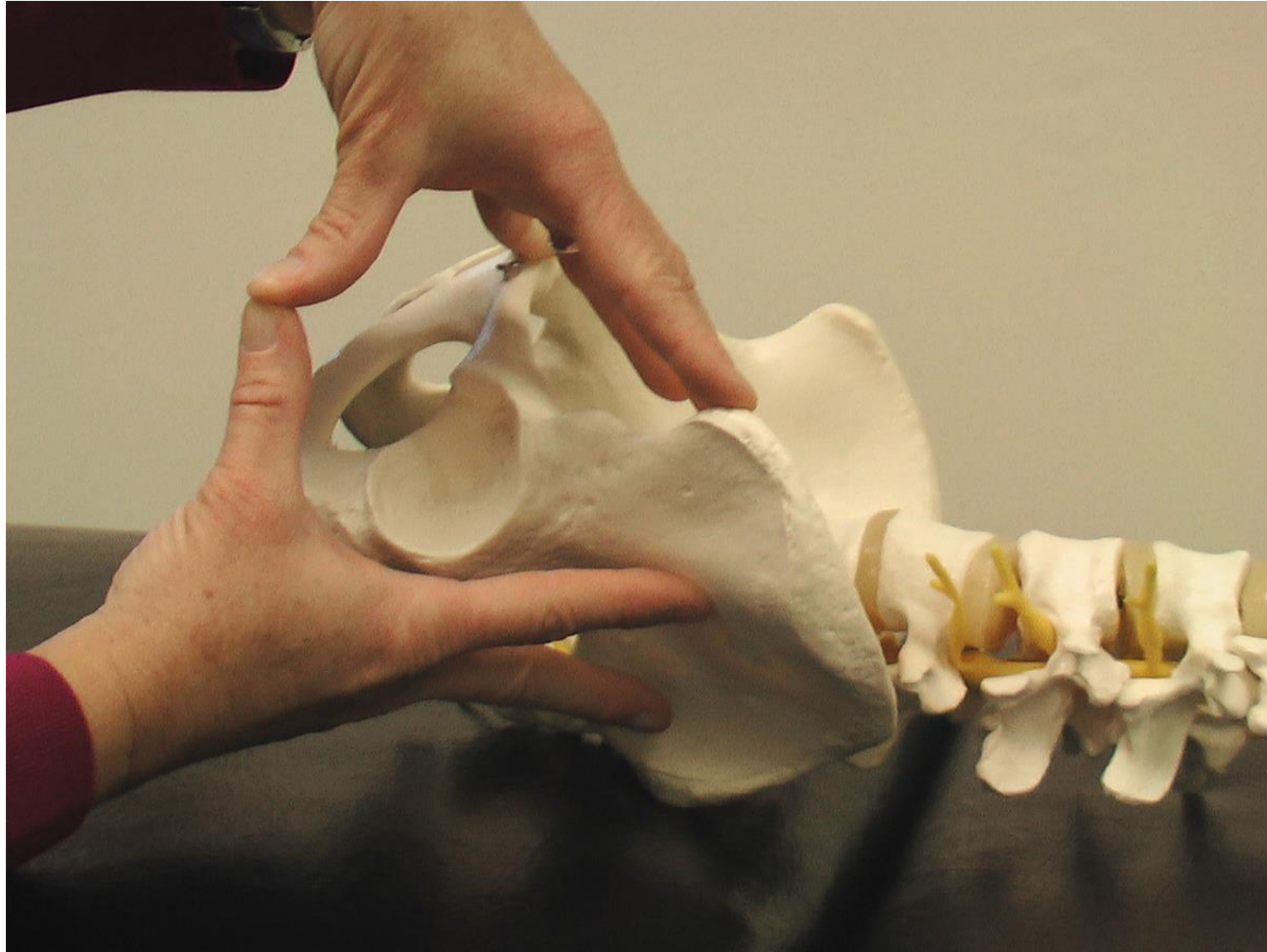
Carreiro, J. Pediatric Manual Medicine: An Osteopathic Approach. Churchill/Livingstone. Page 203

BLT of infant innominate

- Able to grasp all 3 parts of the developing innominate
- Posterior finger pads in SI Joint to eval and treat it
- Notice an alternative hand-hold on the femur using that as a long-lever

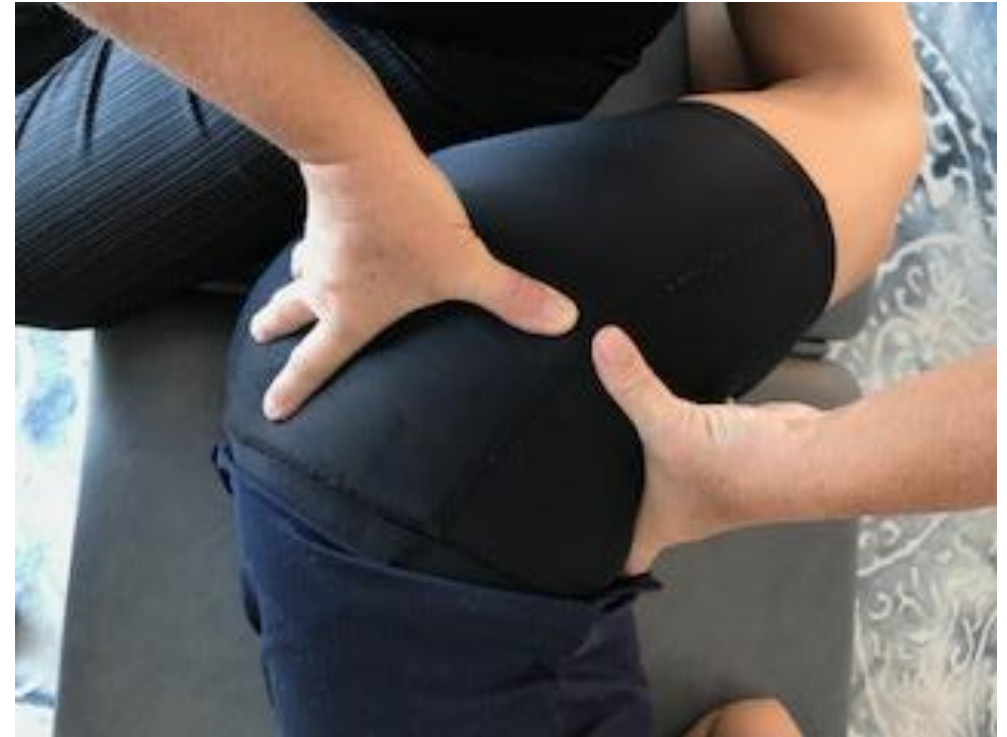





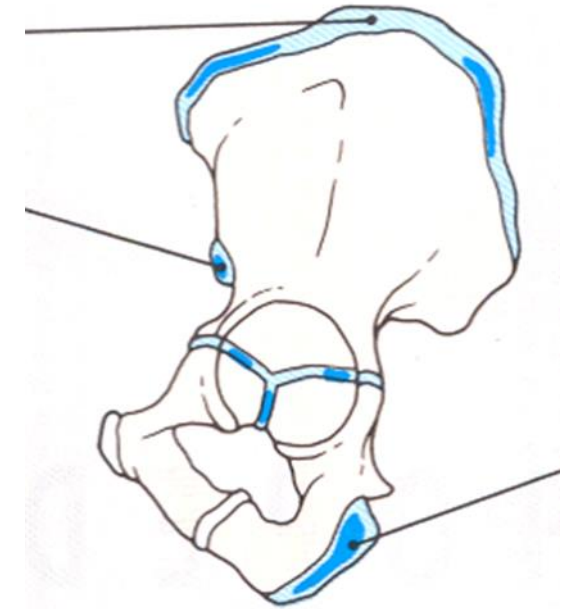
BLT of the innominate & hip – young athlete

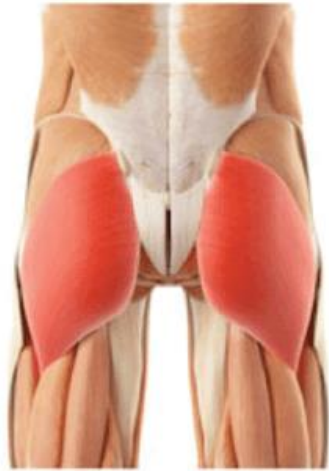- Patient lies on opposite side of dysfunction
- Seated behind the flexed legs, the physician contacts each of the 3 parts of the developing innominate and the femur
- Thumbs:
 - On greater trochanter placing forces along femoral neck into the acetabulum
- Anterior hand:
 - Contact the ASIS and the pubic symphysis
- Posterior hand:
 - Contact the PSIS and ischial tuberosity



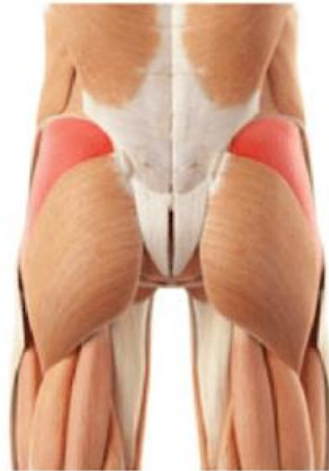BLT of the innominate & hip – young athlete

- The forces of the three parts of the composite bone should resolve at the center of the acetabulum in the Y-shaped epiphysis
- The axis thru the femoral neck and head should align with the center of the Y-shaped epiphysis
- Balancing and molding techniques are applied to address stresses or strains palpated within the musculoskeletal system
- This technique is more effective in younger children

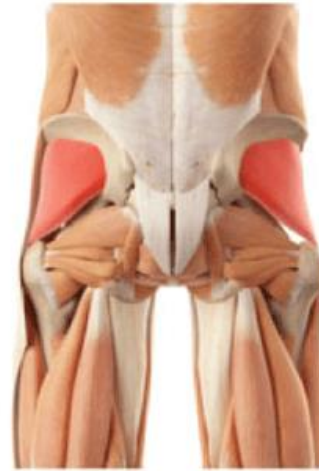



Gluteus Maximus

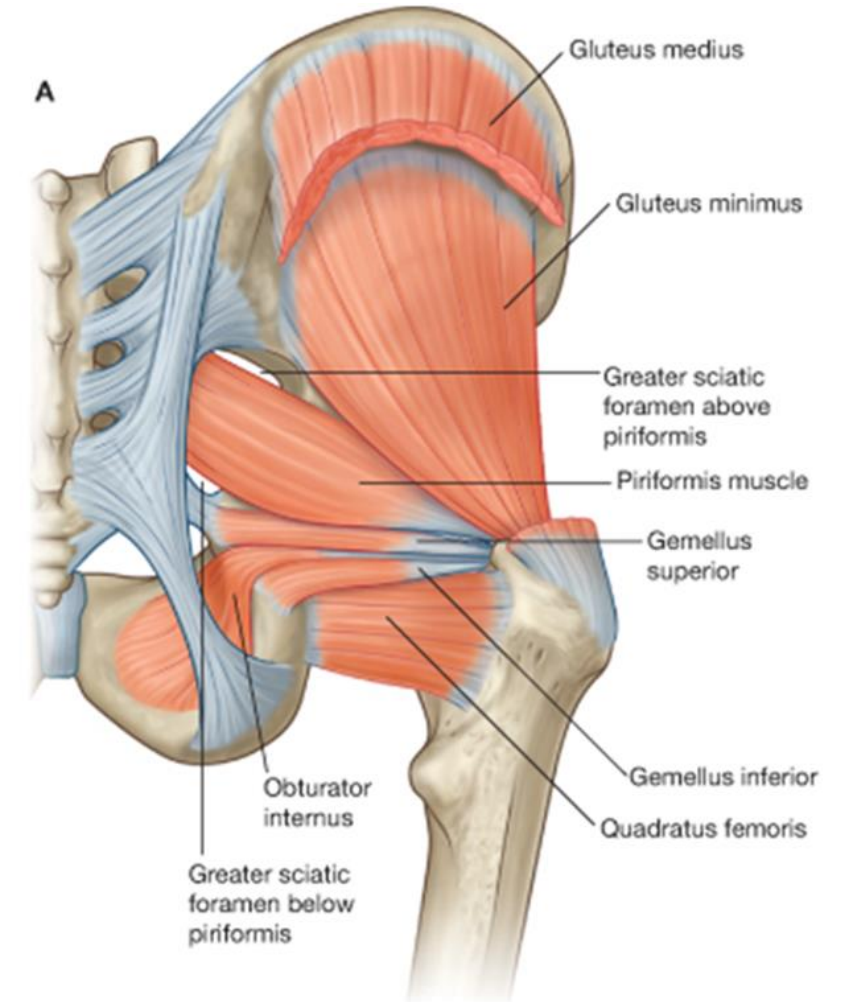


Gluteus Medius



Gluteus Minimus

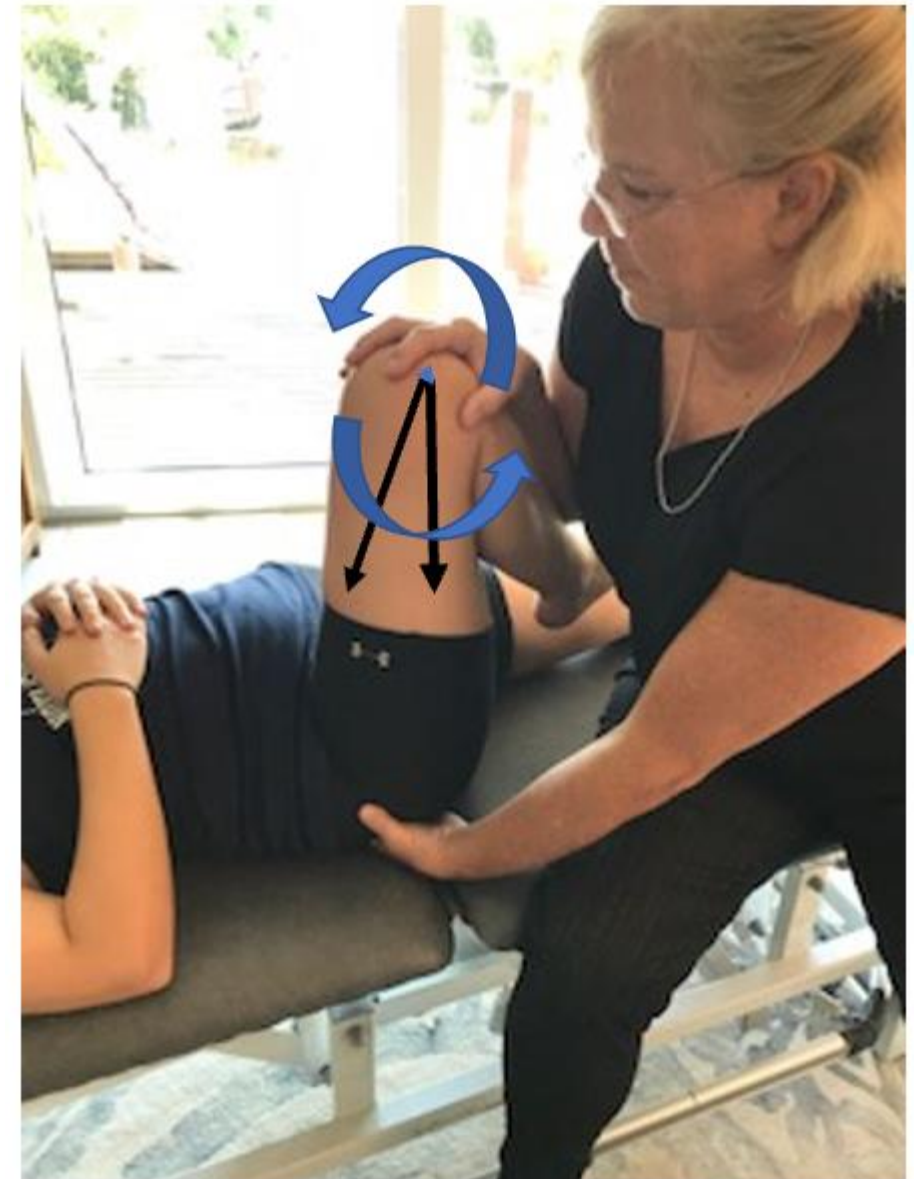<https://westcoastsci.com/general-blog/2018/6/15/what-exactly-are-the-glut-muscles>



BLT Rotator Muscles of the Hip

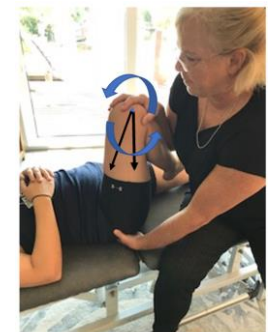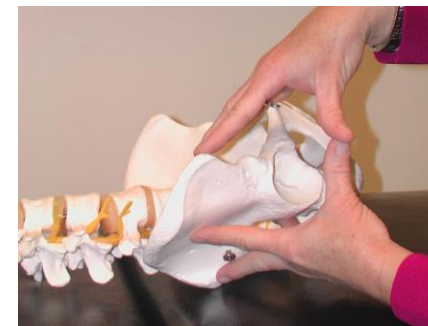
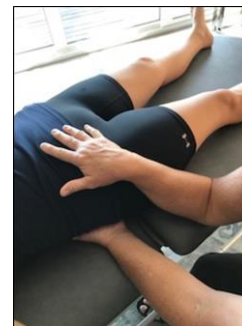
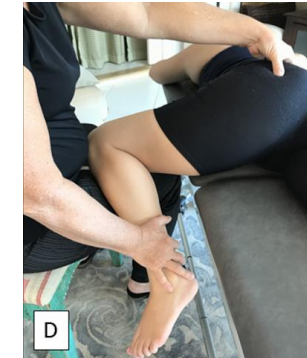
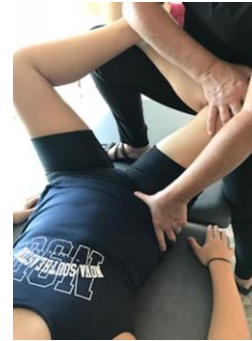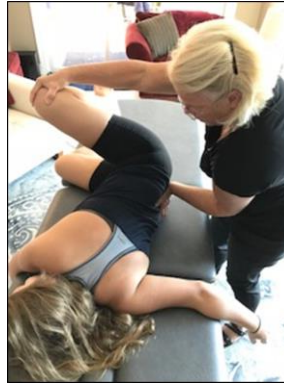
- Patient supine
- Physician sits on ipsilateral side
- The posterior hand placed under the innominate, contacting the femur (thumb), the ilium and ischium (palm and fingers)
- The patients hip is at 90 deg and the knee flexed with the physician's other hand grasping the knee
- Use the femur as a long lever to asses and treat the myofascial tissues
- With the thumb, compress and distract thru the femur towards the acetabulum to assess flexibility at the hip joint
- Balance tension is obtained in these tissues by gently introducing different vectors of motion into the hip
 - IR, ER
 - ABD and ADD
 - Compression, Traction
 - Gapping at the joint
- Once balanced tension is obtained in all directions, hold until tissue texture changes occur
- Return to rest and reassess

Long Lever Technique



Hands-on practice session

- Generalized SIJ articular technique
- Counterstrain Technique:
 - Iliopsoas
 - Piriformis
 - Hip ADDuctors
- BLT:
 - Innominate – adolescent and adult
 - “Composite” Innominate – infant and child
 - Hip rotator muscles with the long lever technique



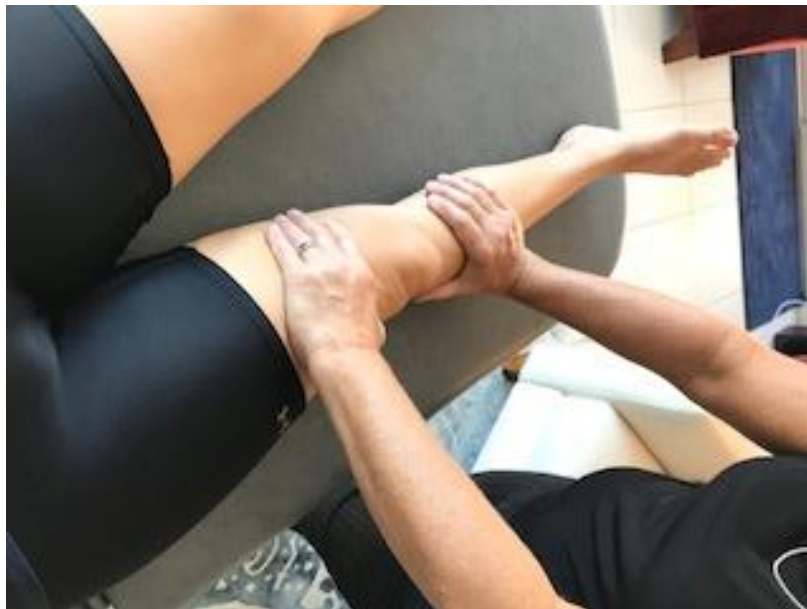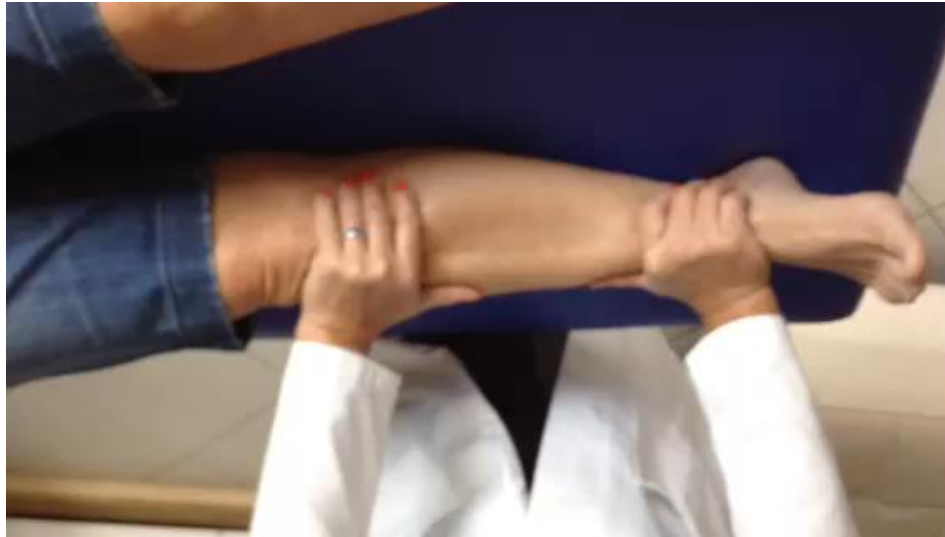OMT Hip and Knee

- OMT
 - MET (age appropriate)– femur, tibia
 - BLT – distal femur and proximal tibia
 - Balance across the joint
 - Check all related muscles for spasm, edema
 - Check popliteal muscle tension
 - Hamstring spread and mfr of popliteus m
 - BLT – align femur with acetabulum
 - BLT – fibula and crural interosseous membrane

MET of an ER hip: hip extended or flexed

- MET – direct technique
 - Take the tissues toward the restrictive barrier into IR
 - Ask the patient to ER their hip
 - Hip Extended – “roll the foot outward”
 - Hip Flexed – “pull your ankle into my hand”
- Hold the isometric contraction 3-5 sec
- Relax for at least a few seconds to allow the post-isometric relaxation at the neuromuscular junction to occur
- Take to new barrier
- Repeat procedure 3-5 times
- Retest
- For IR hip – reverse the directions



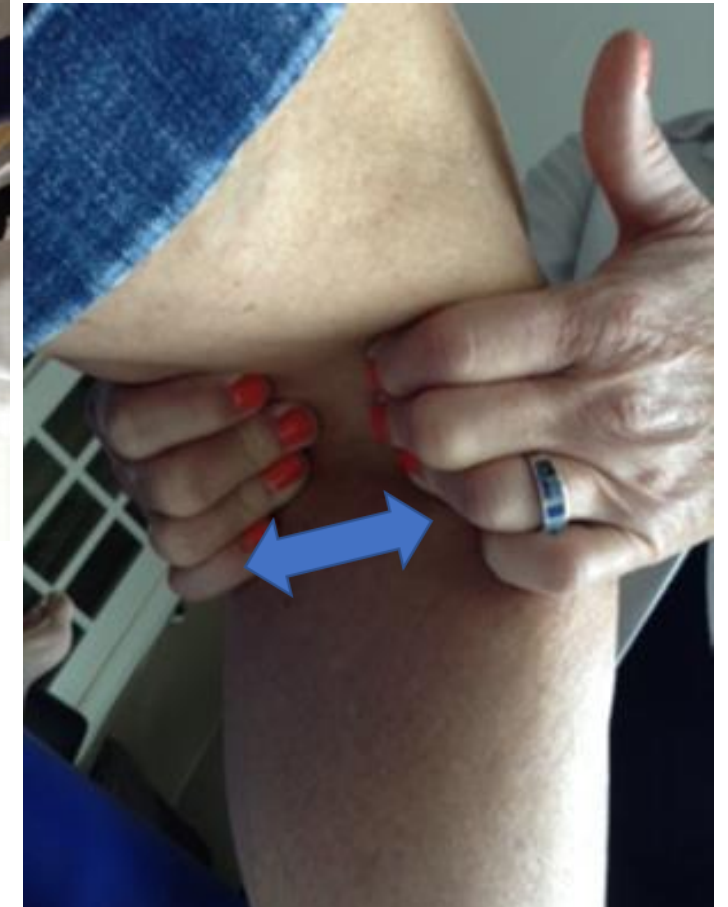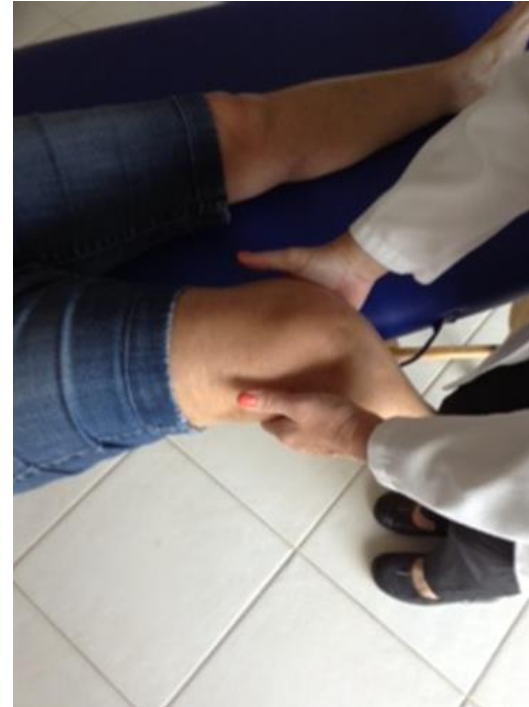


MET of an ER tibia

- With both hands firmly on the tibia
 - Internally rotate the tibia to the restrictive barrier
- Have the patient externally rotate the limb gently and hold and isometric contraction for 5 seconds
- Release
- Wait for a post-isometric relaxation of the tissues
- Bring to the new restrictive barrier
- Repeat 3-5 times
- Alternate hand position
 - One hand on the distal femur to stabilize that bone
 - Distal hand on the proximal tibia to mobilize that bone

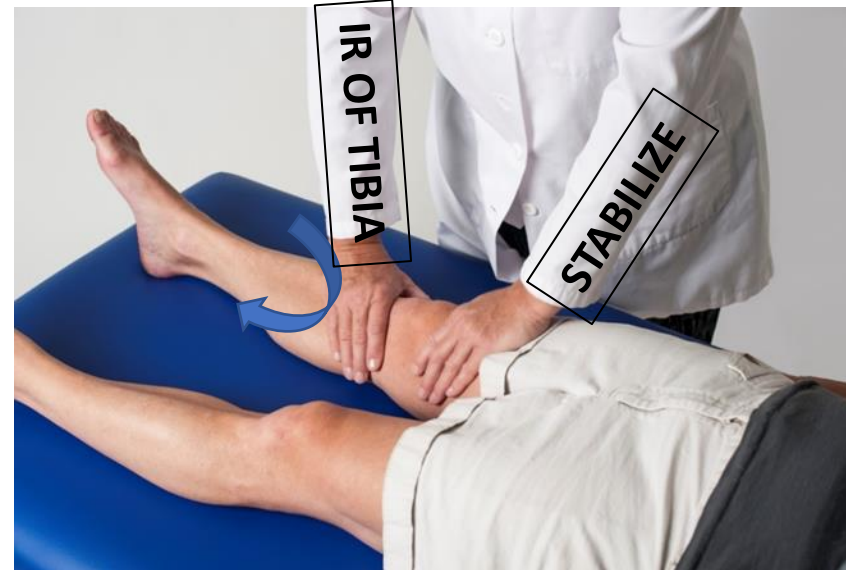Popliteal (hamstring) spread – lymphatic drainage

- Patient is supine with the affected leg and thigh off the side of the table
- Stabilize the patient's leg between your own legs
- Operator places his fingers in the popliteal fossa and exerts a mild traction, spreading the medial from the lateral hamstring tendons apart
- Hold traction for 15-60 seconds or until release or warmth is felt



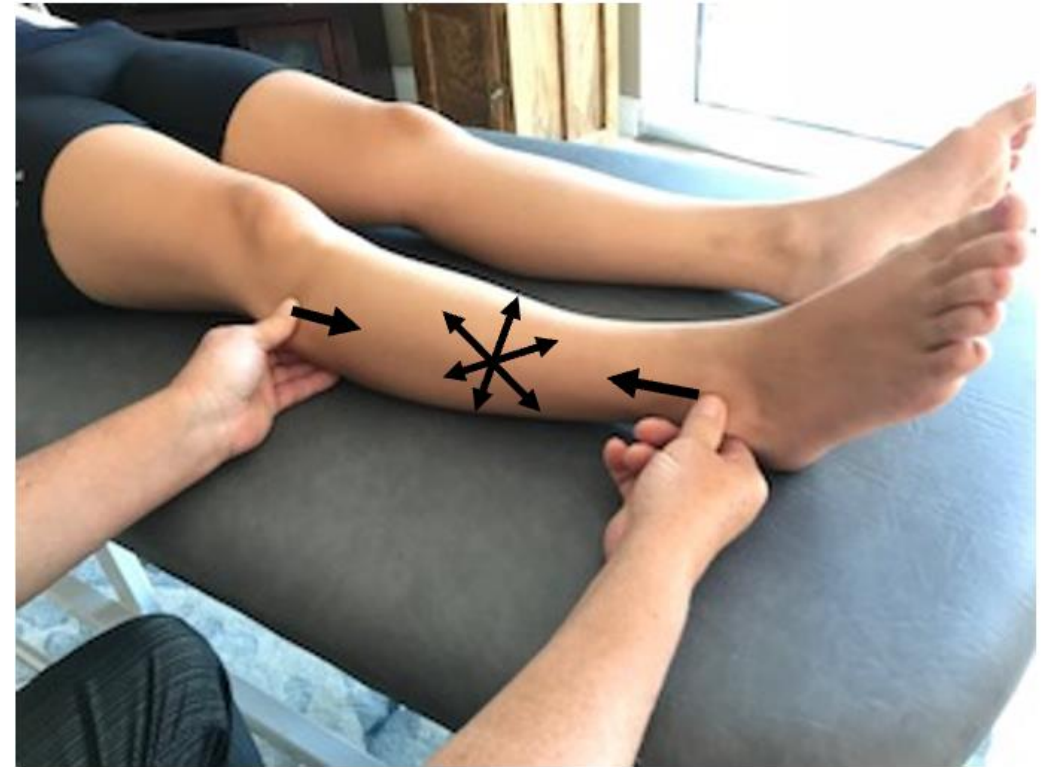
Knee Treatment – BLT of the FLUIDS

- Stabilize the femur with the proximal hand
- Find (within the CRI) the “balance point” or mid-range where the cranial motion of the tibia matches up with the cranial motion of the femur
- Hint: it will be towards ease

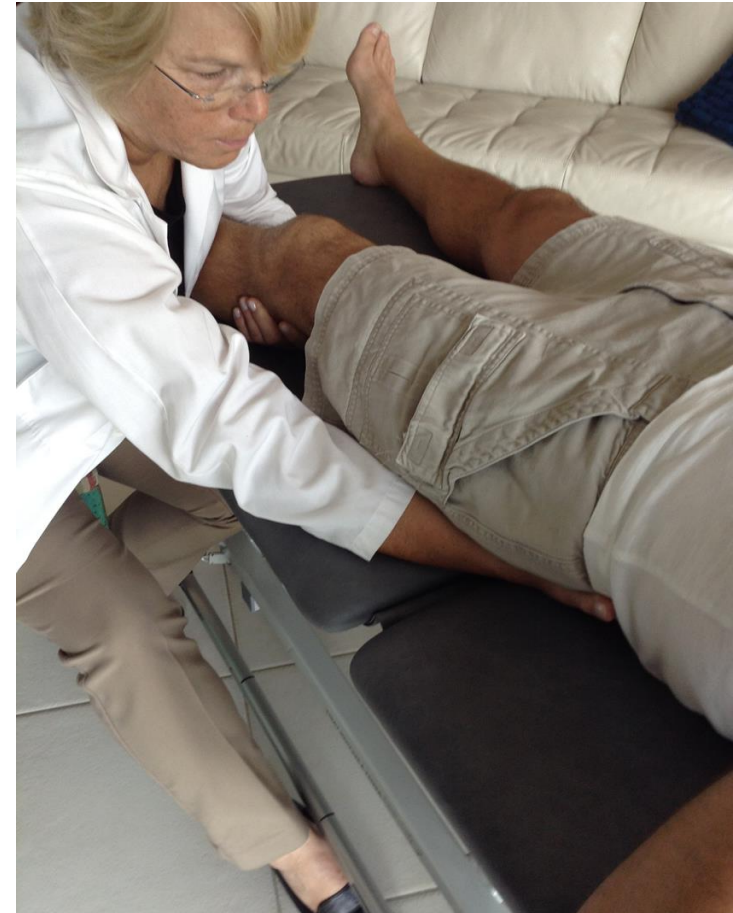
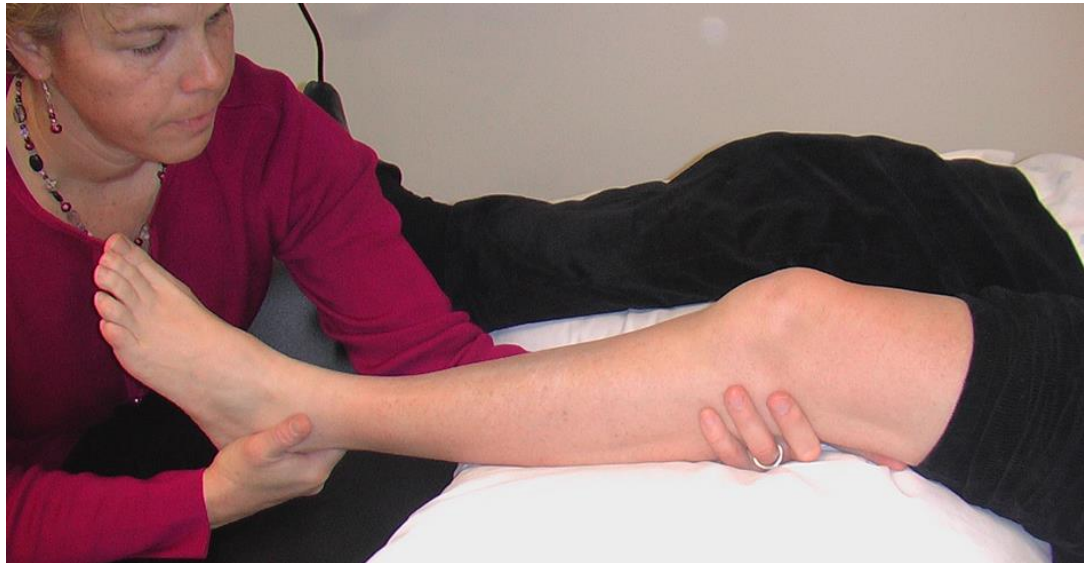
BLT of the crural interosseous membrane and fibula

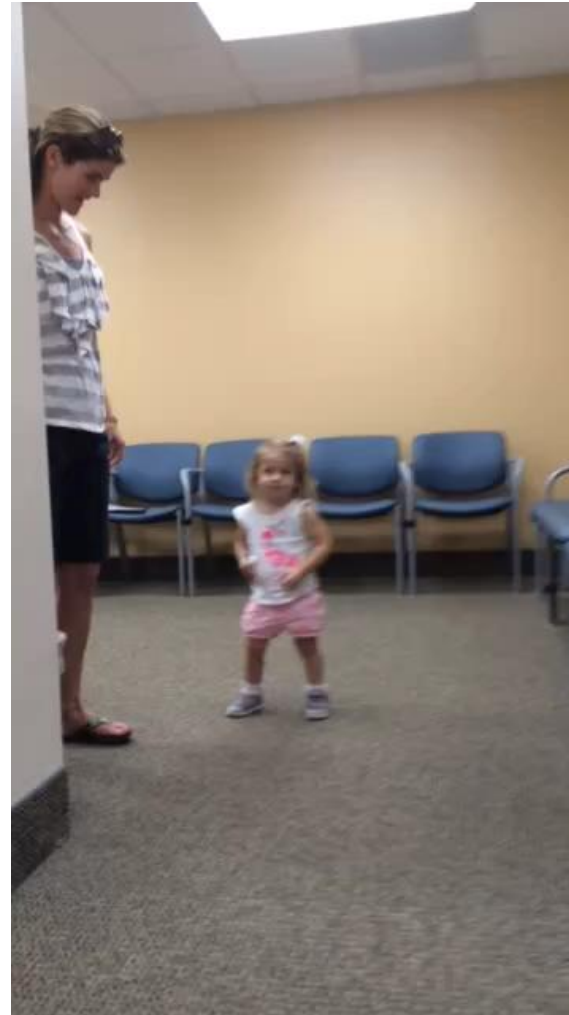- Fibula is a long bone and has a “seesaw” type motion
- Seated beside the limb to be treated
- Grasp the proximal and distal fibula
- Take the bone into 3 planes of motion:
 - Rocking = posterior at the head = anterior at the lateral malleolous
 - Superior and inferior glide
 - Traction – towards you
- Find the “balance point” in all of these planes of motion
- Stack the motions
- Hold the stacked position until you feel a tissue texture change
- Slowly release



Fluid techniques to integrate your treatments and allow the CRI to organize the extremity.



Dev delayed child
– gait before OMT



Dev delayed gait –
holding hand

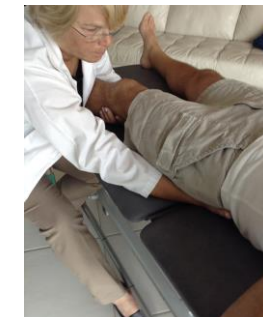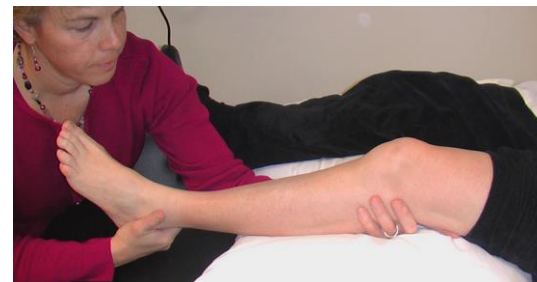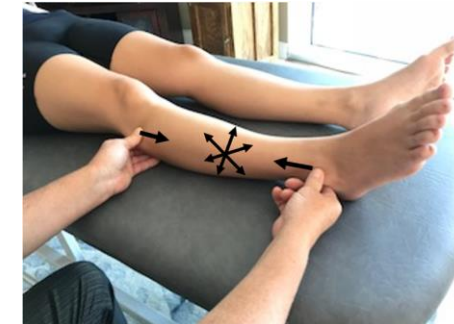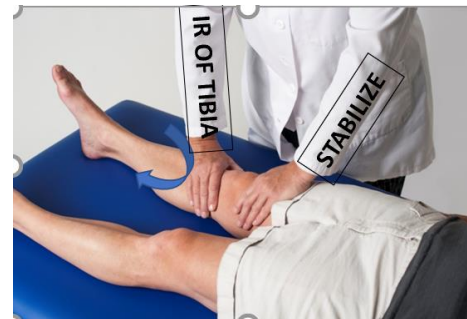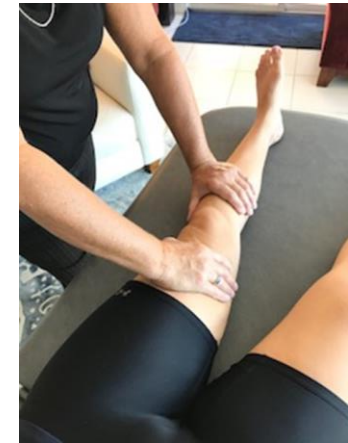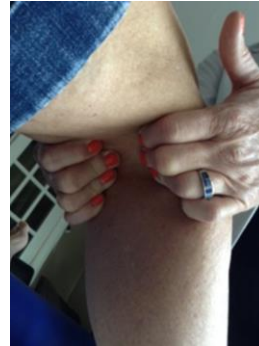


Dev delayed child
gait after OMT



Hands on practice session

- Muscle Energy Technique:
 - Hip ER and IR
 - Tibial ER and IR
- Lymphatic Technique
 - Popliteal Spread
- BLT – Fluid Technique across the knee joint
- BLT – Fibula
- BLT – Fluid Techniques
 - Crura
 - Femur



References:

- Carreiro, J; An Osteopathic Approach to Children, 2nd ed. Elsevier, Philadelphia, 2009.
- Ward, R exec ed: Foundations for Osteopathic Medicine, 2nd Edition. Williams & Wilkins, Baltimore, 2003.
- Yates H, Glover J: Counterstrain Handbook of Osteopathic Technique. Yknot Publishers, Kirksville, 1995
- Various anatomy and other images from the internet modified for presentation
- M1 and M2 handout images from UNECOM & KPCOM
- Carr JB, Yang S, Lather LA. Pediatric Pes Planus: A State-of-the-Art Review. Pediatrics. 2016;137(3):e20151230
- <https://medical-dictionary.thefreedictionary.com/genu+valgum>
- <https://www.today.com/parents/why-w-sitting-really-not-so-bad-kids-after-all-t69806>
- <http://pediatrics.aappublications.org/content/early/2016/02/15/peds.2015-1230>